

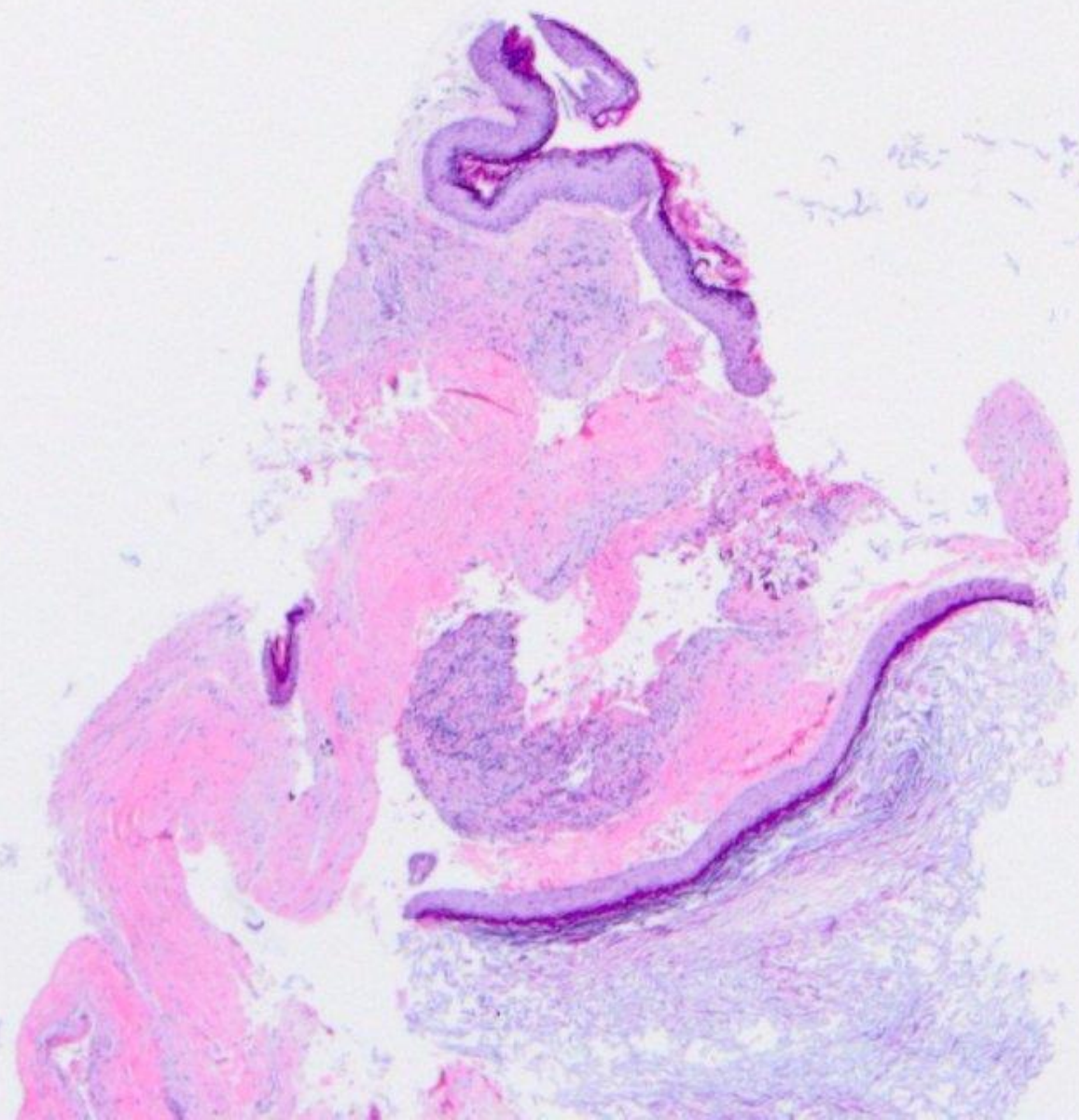
# Oral Histopathology

## Series 28

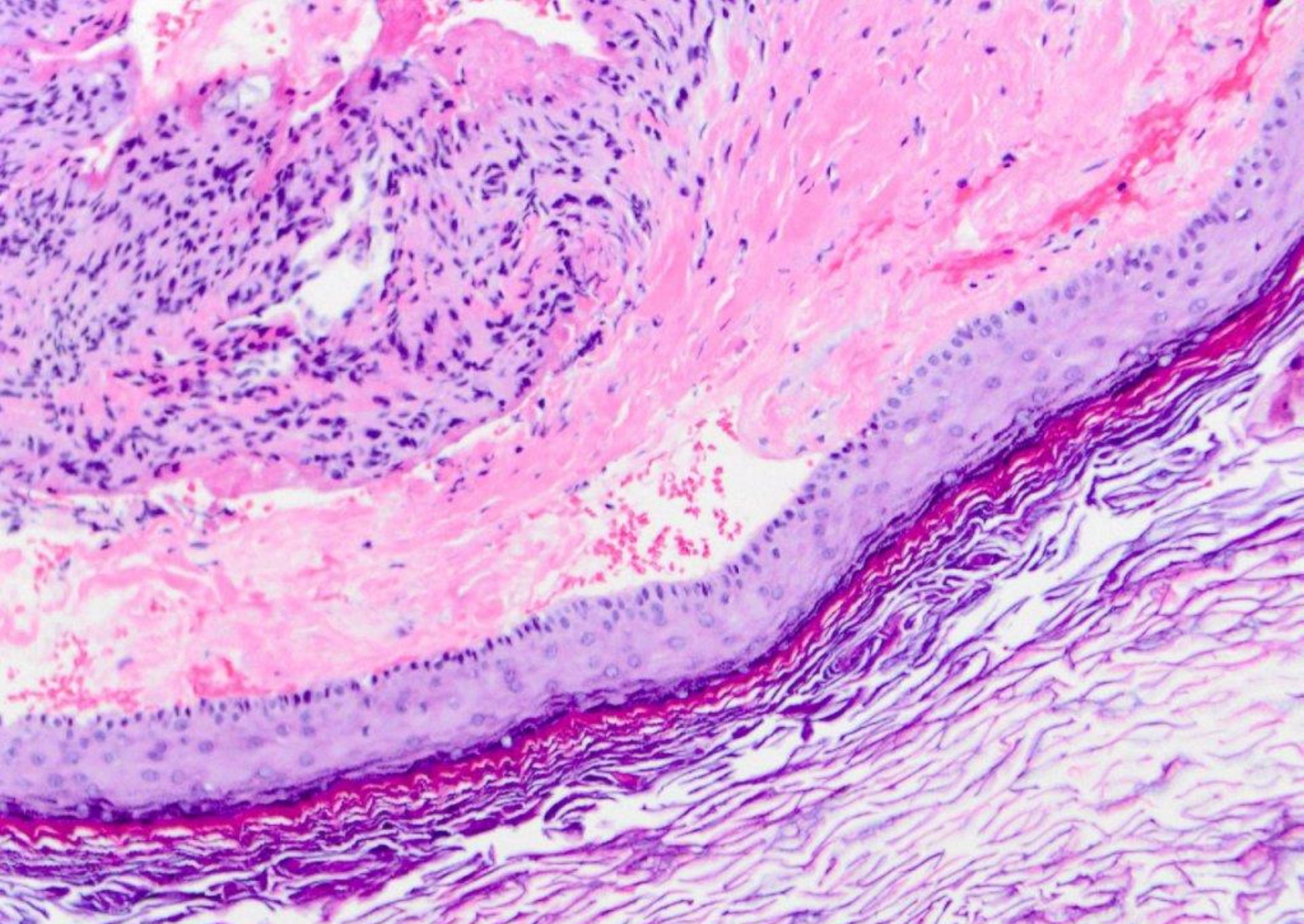
**DAVID E. KLINGMAN, DMD**

*Diplomate, American Board of Oral and Maxillofacial Pathology*

*Diplomate, American Board of General Dentistry*

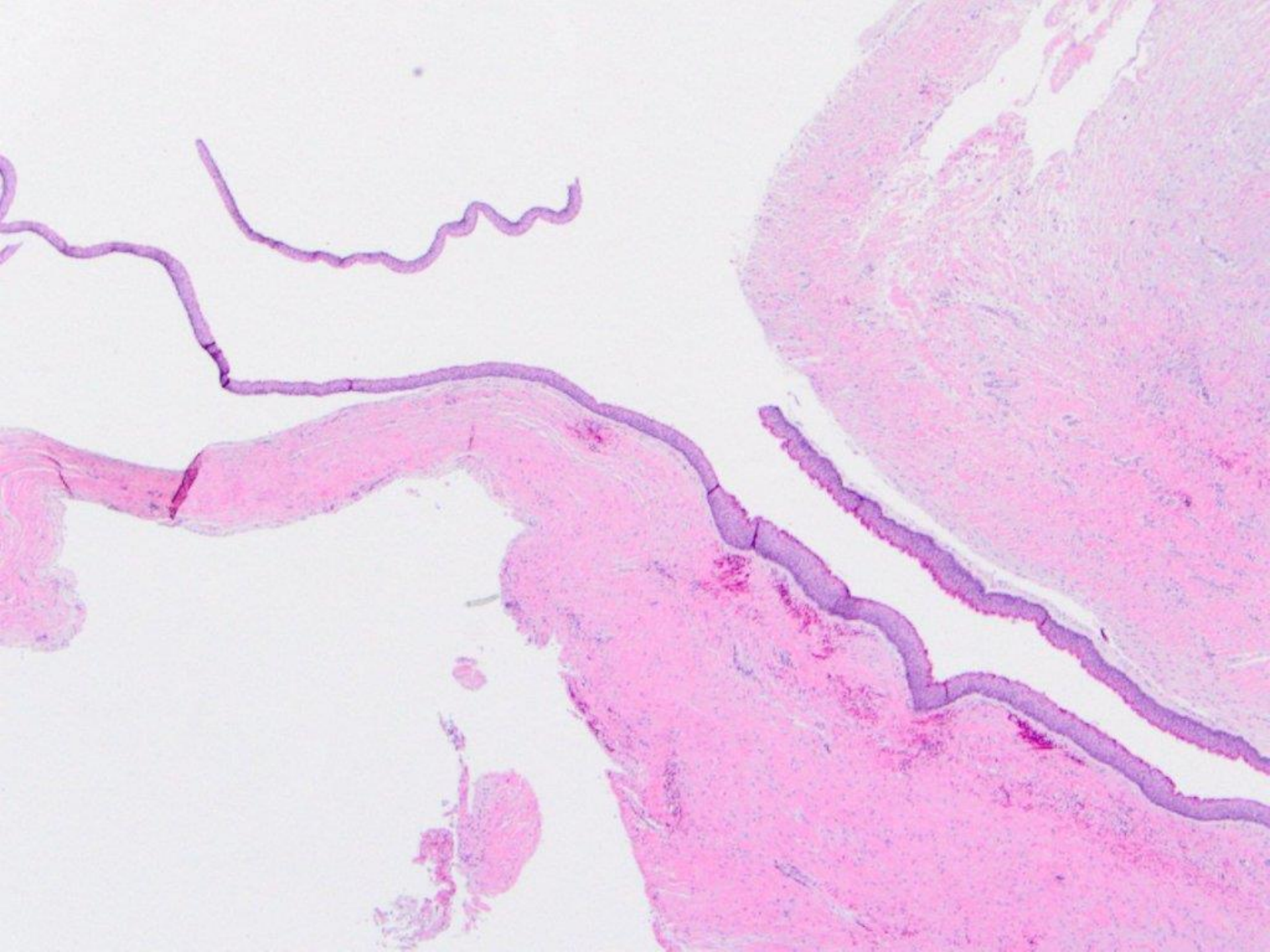




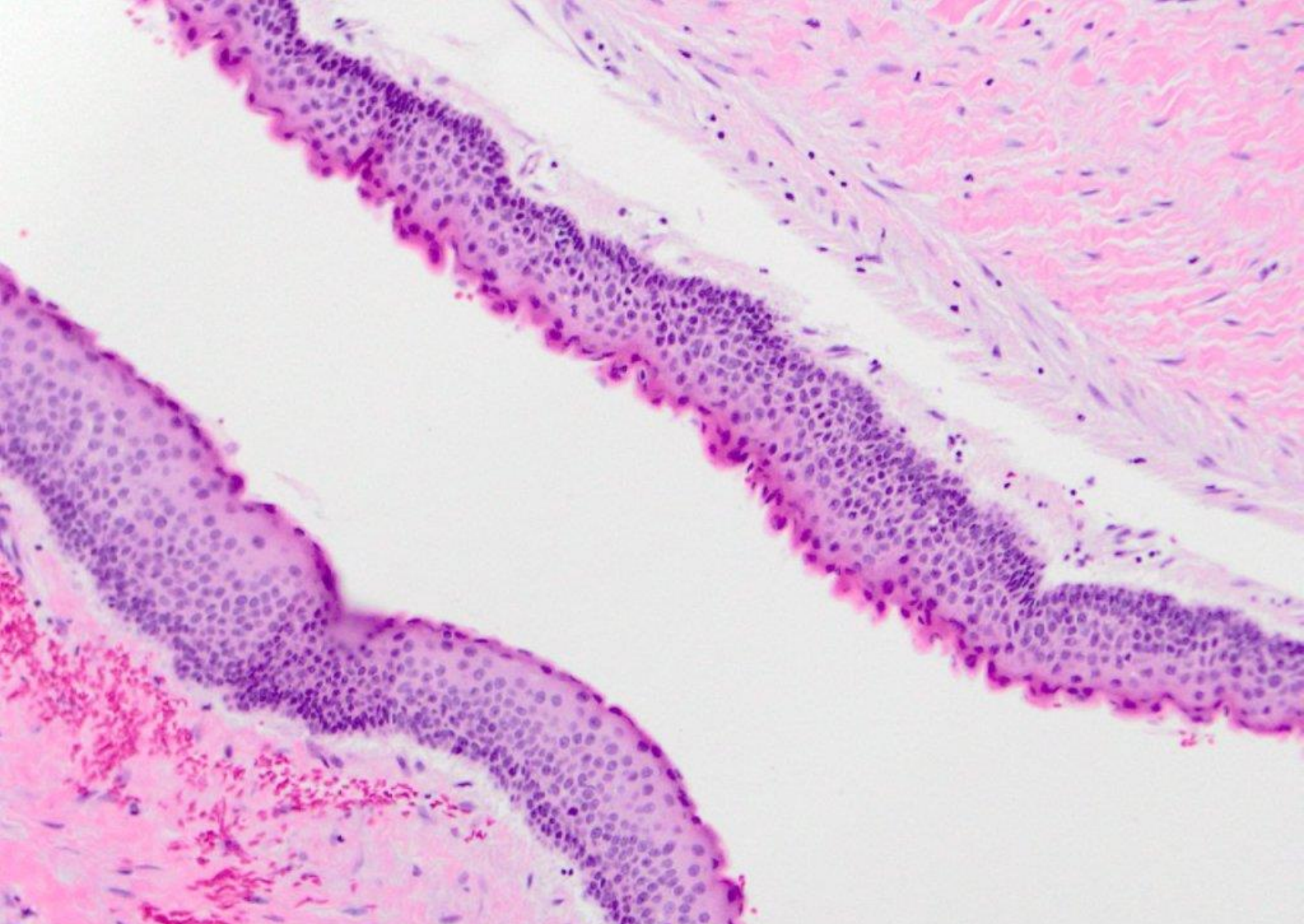


orthokeratinizing odontogenic cyst



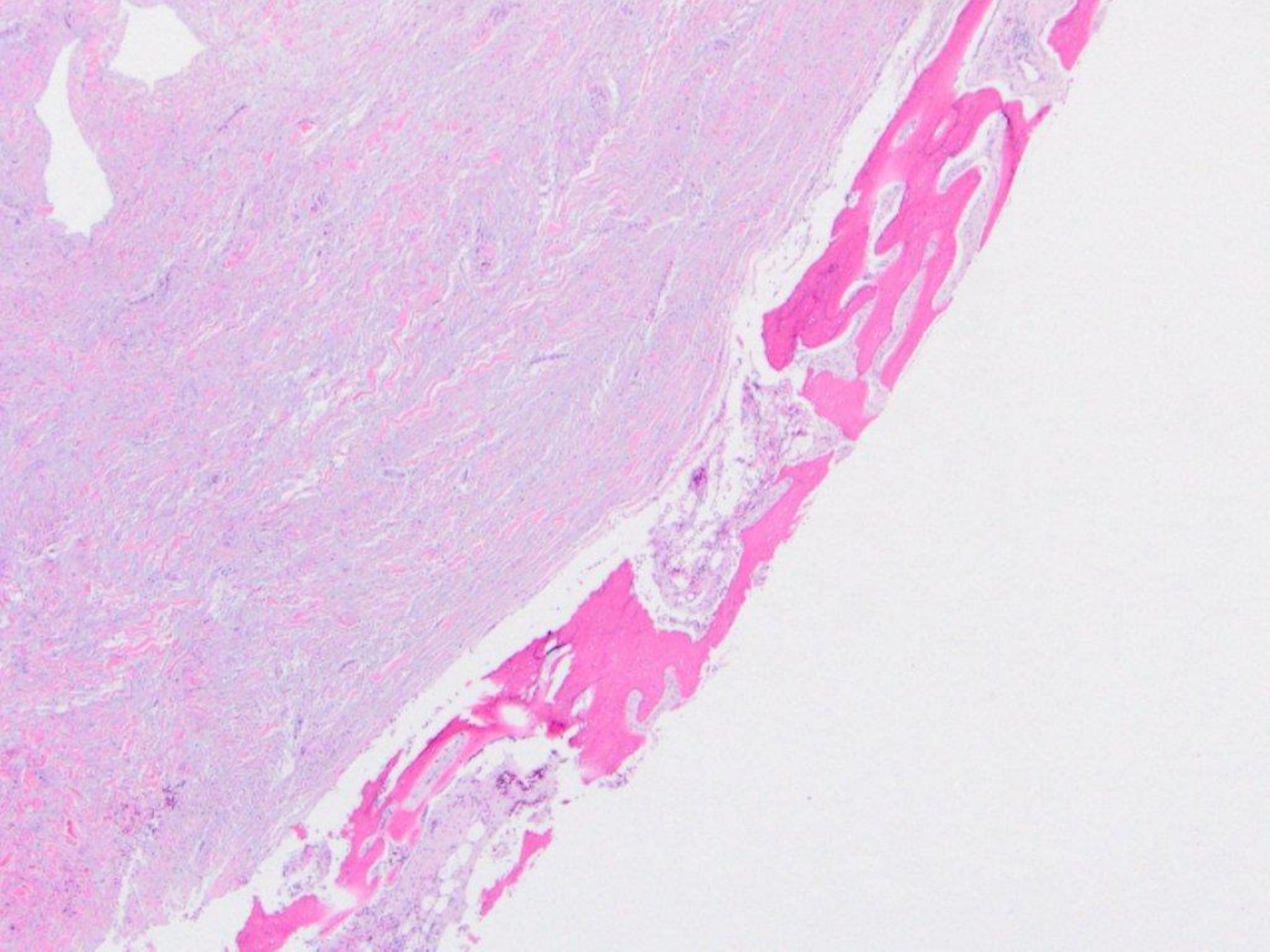




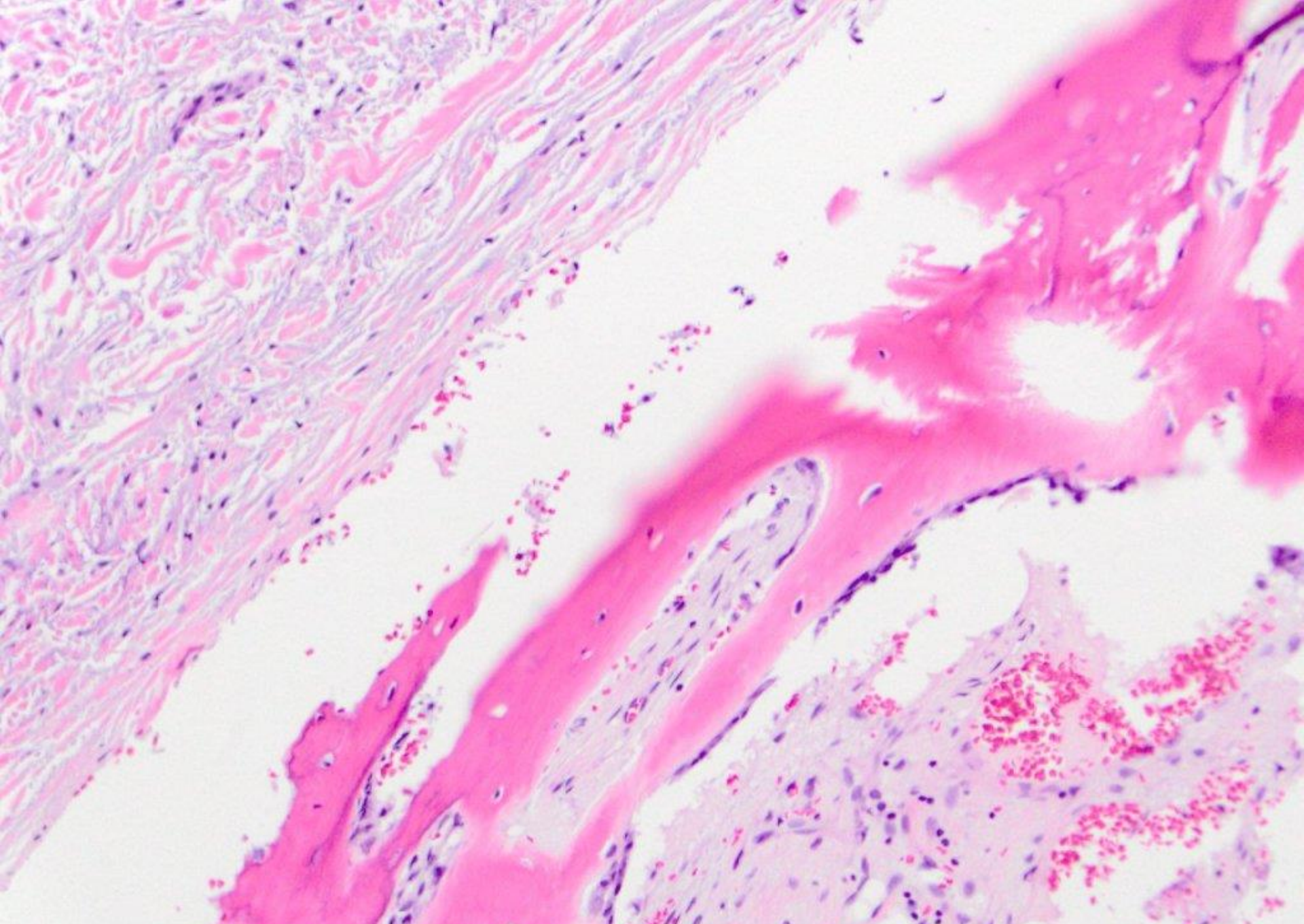


odontogenic keratocyst (keratocystic odontogenic tumor)



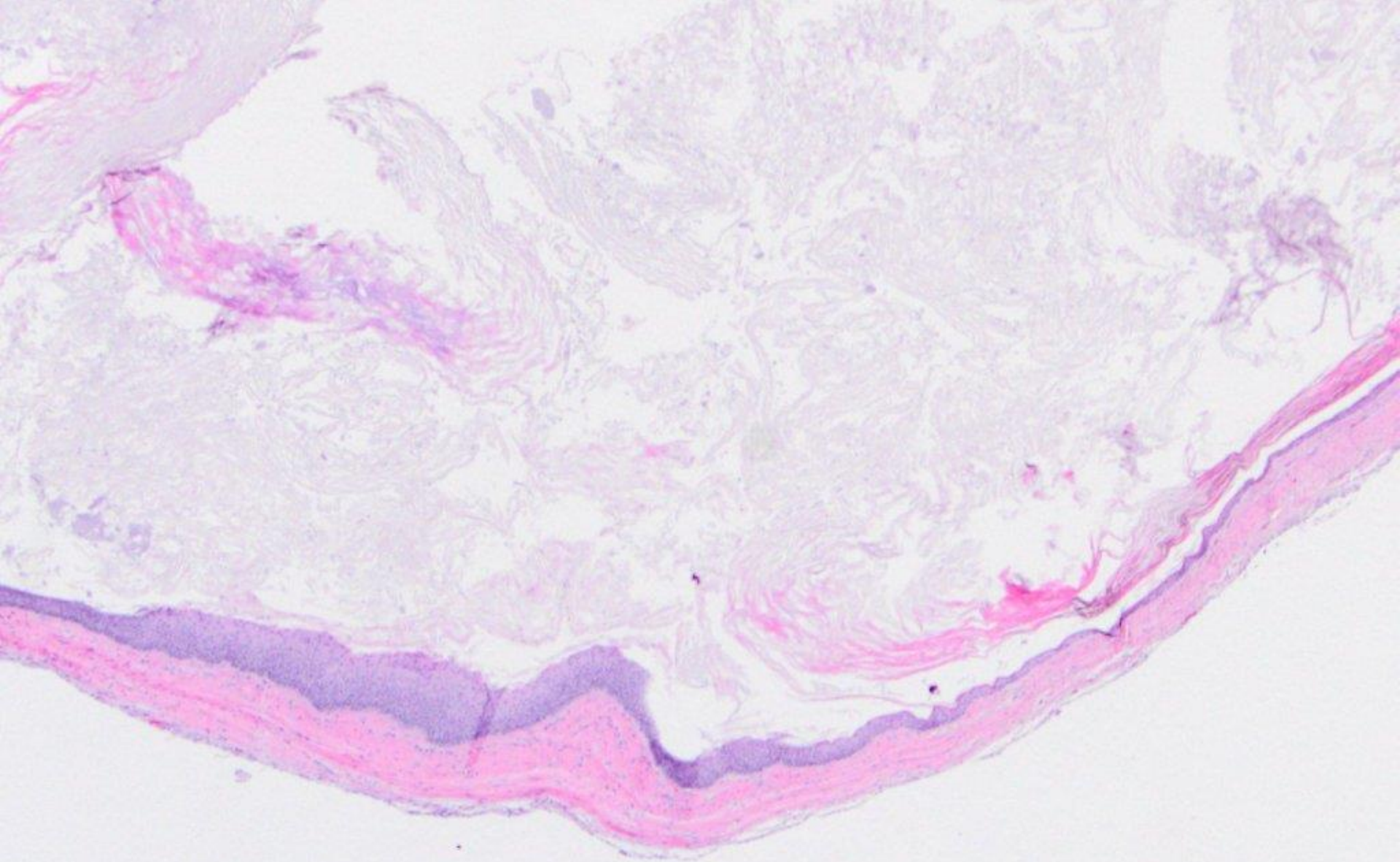




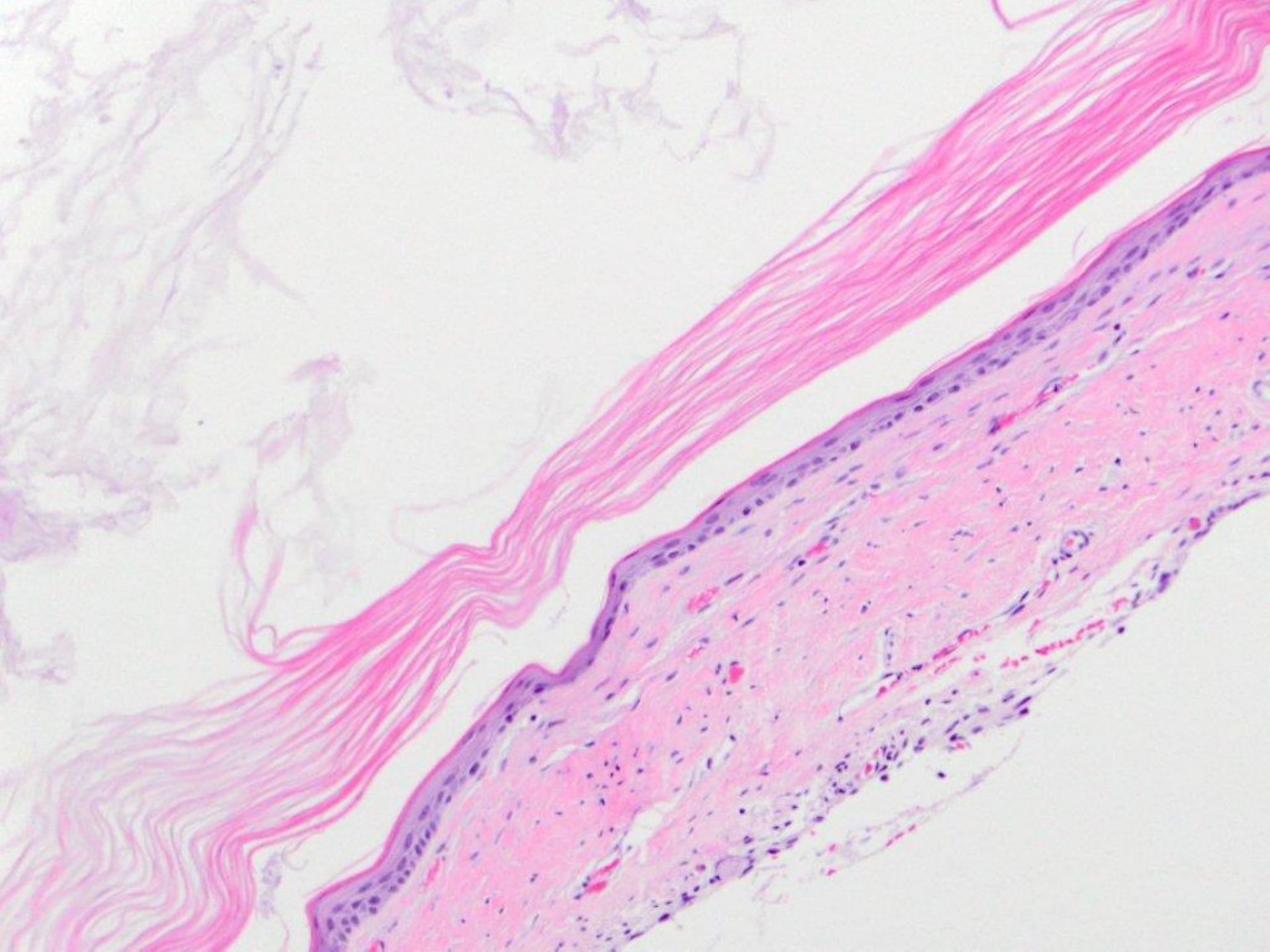


odontogenic keratocyst (keratocystic odontogenic tumor); cortical plate

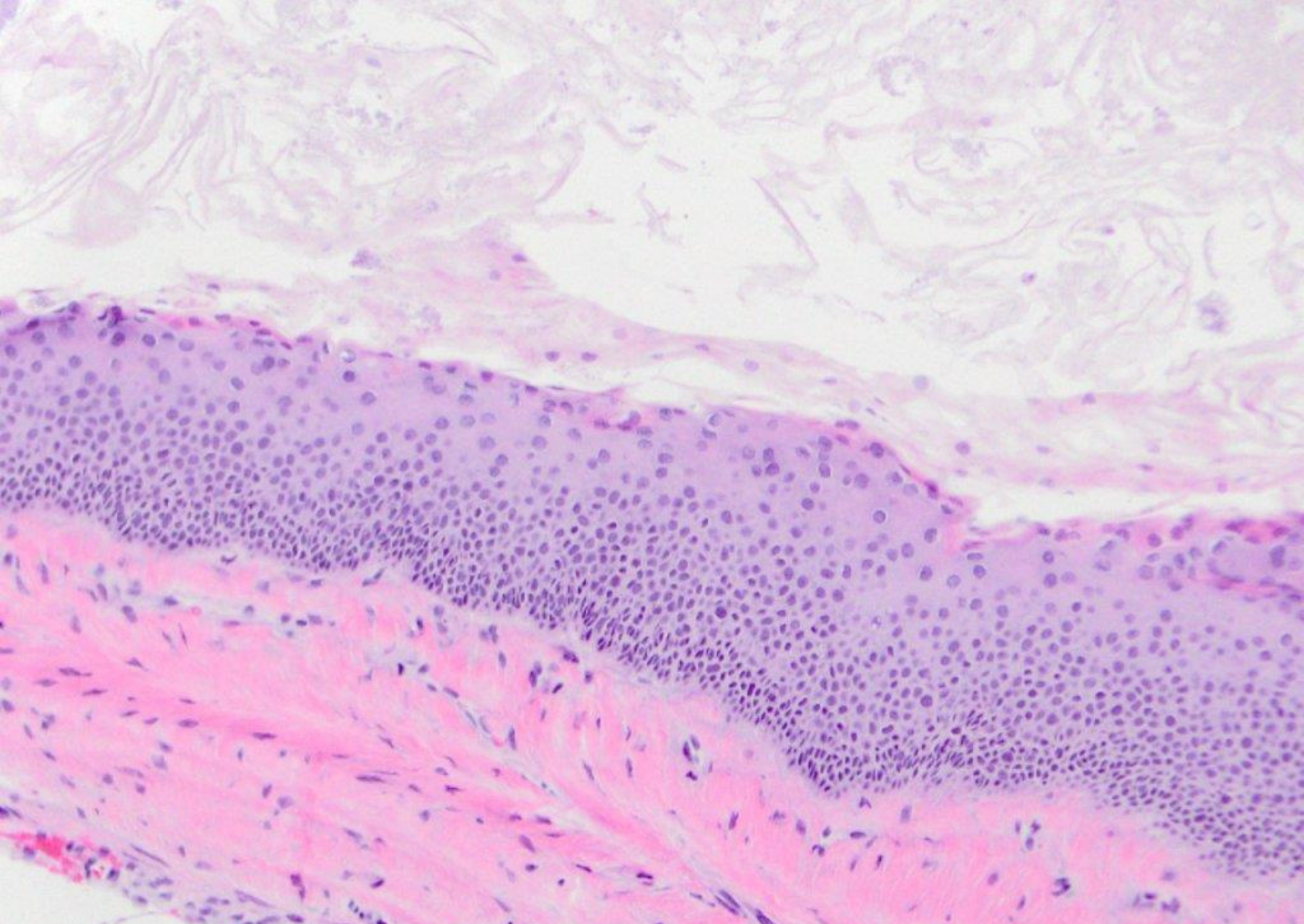








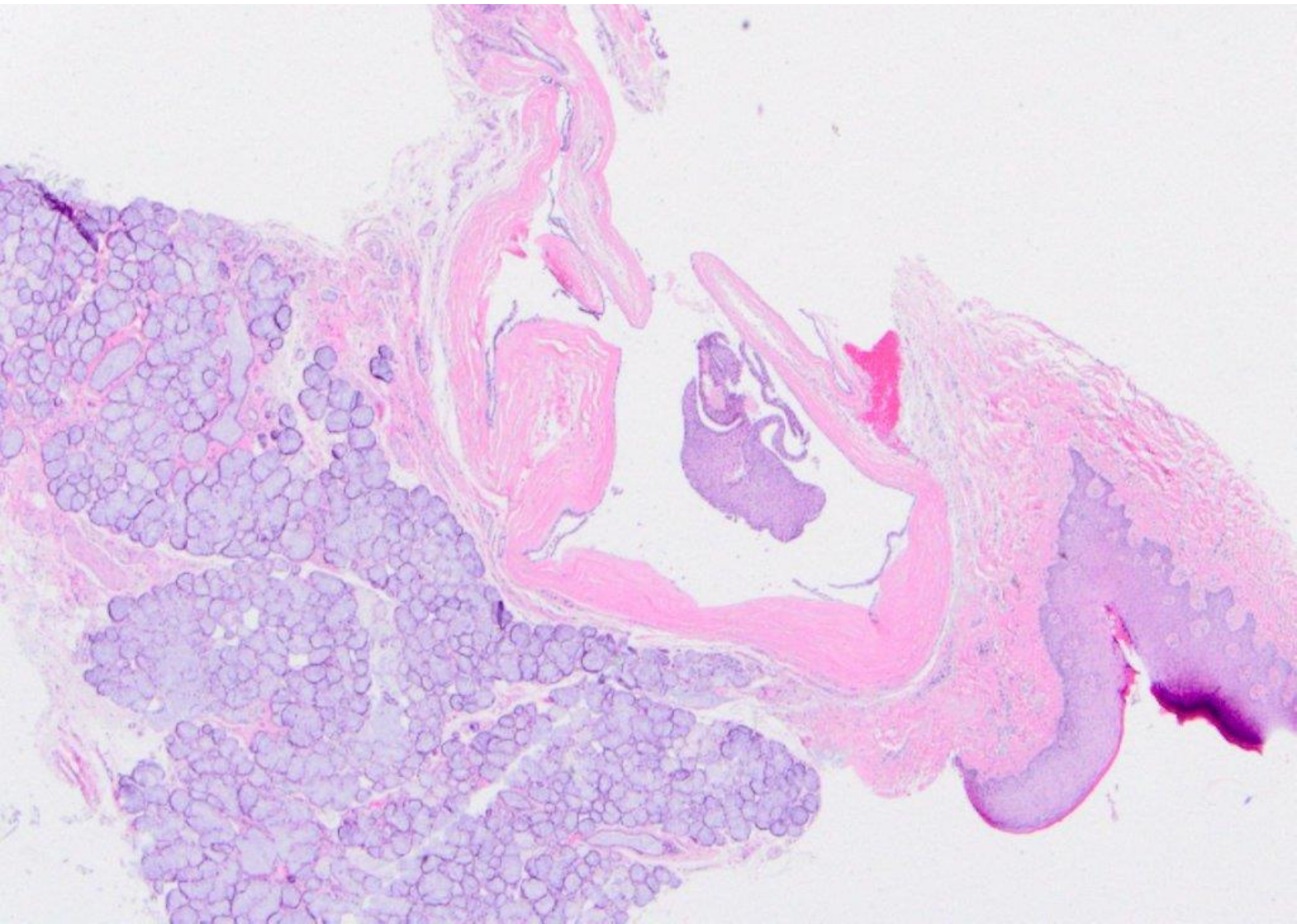




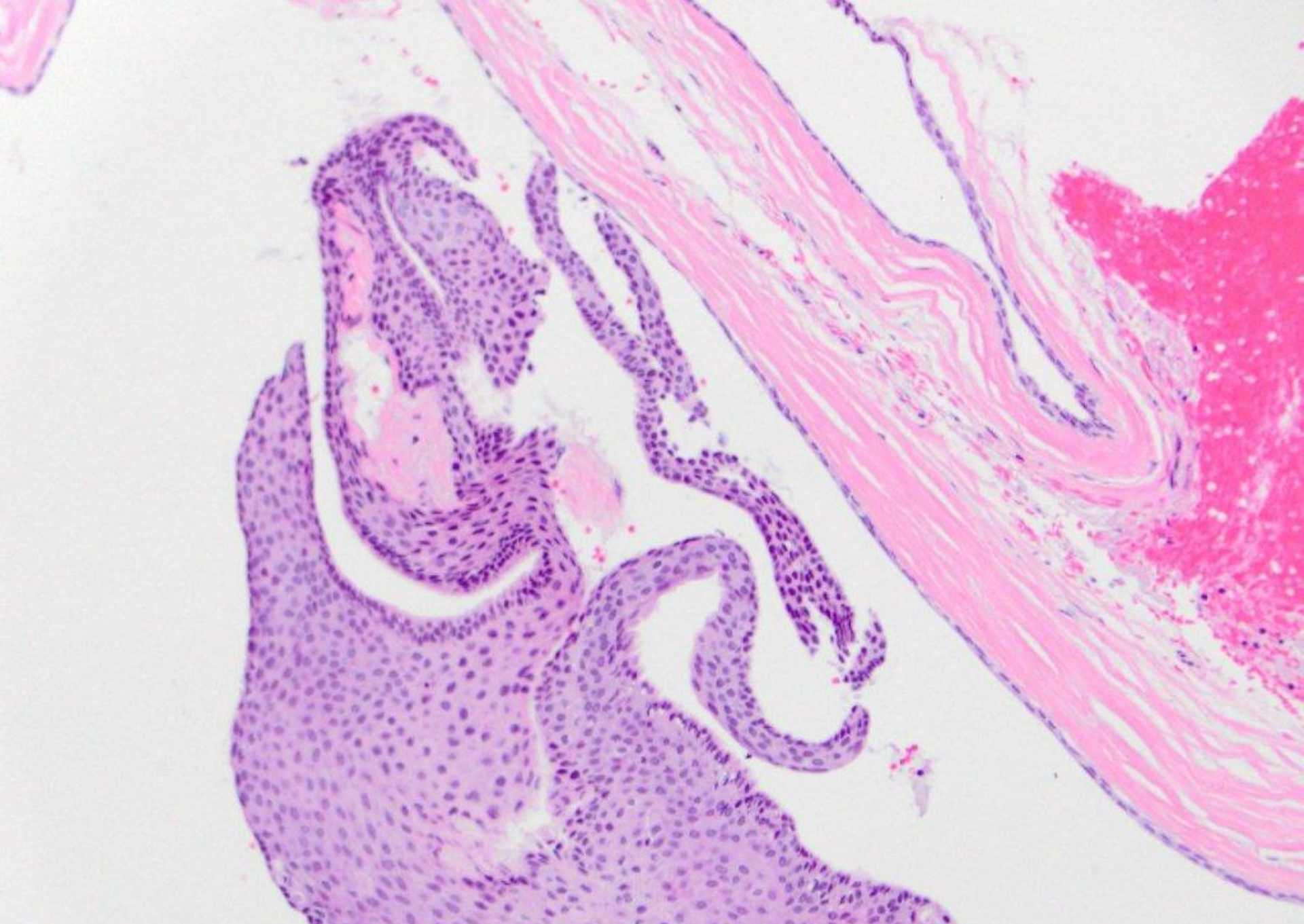
odontogenic keratocyst (keratocystic odontogenic tumor)



described as being on palate



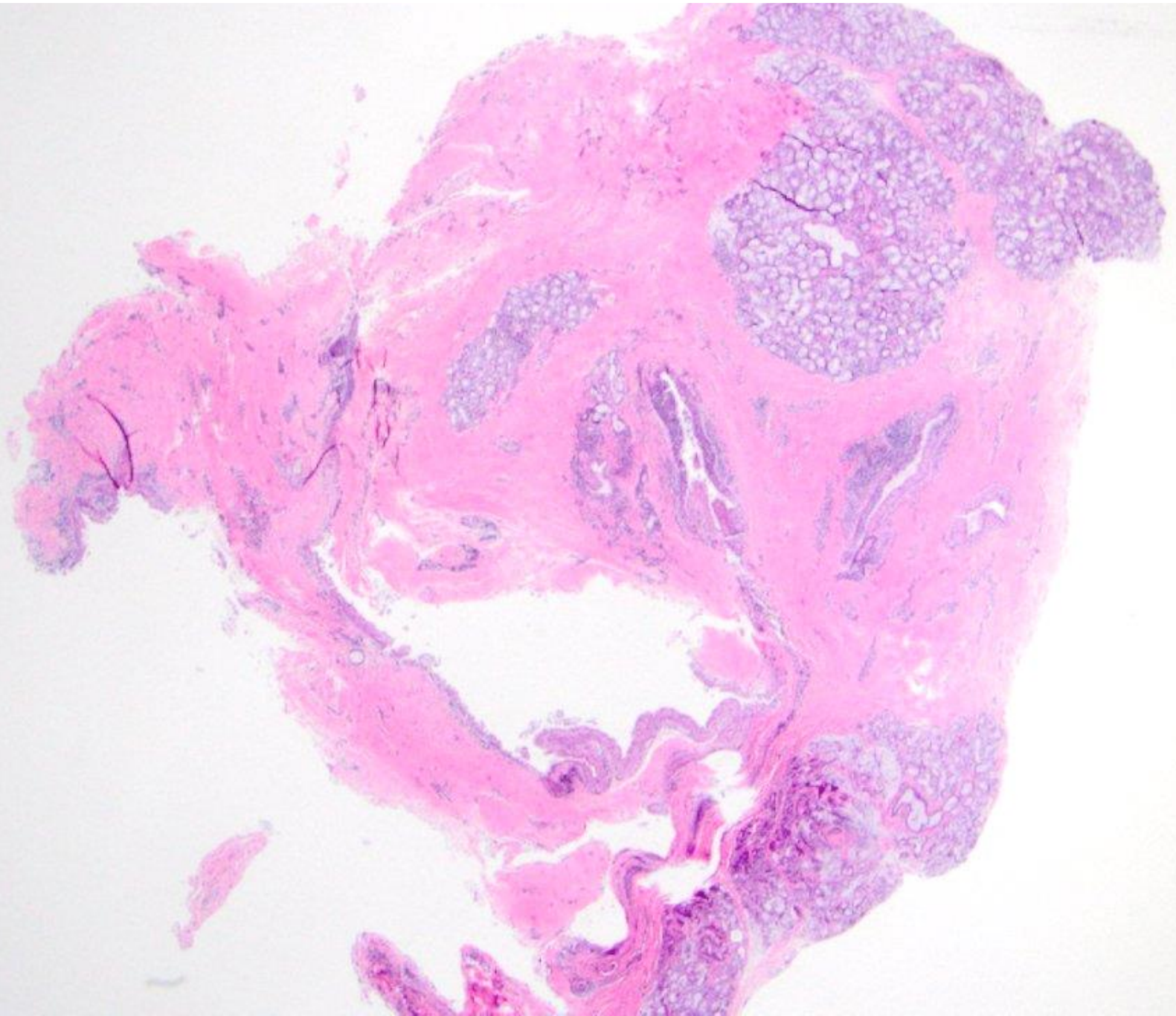




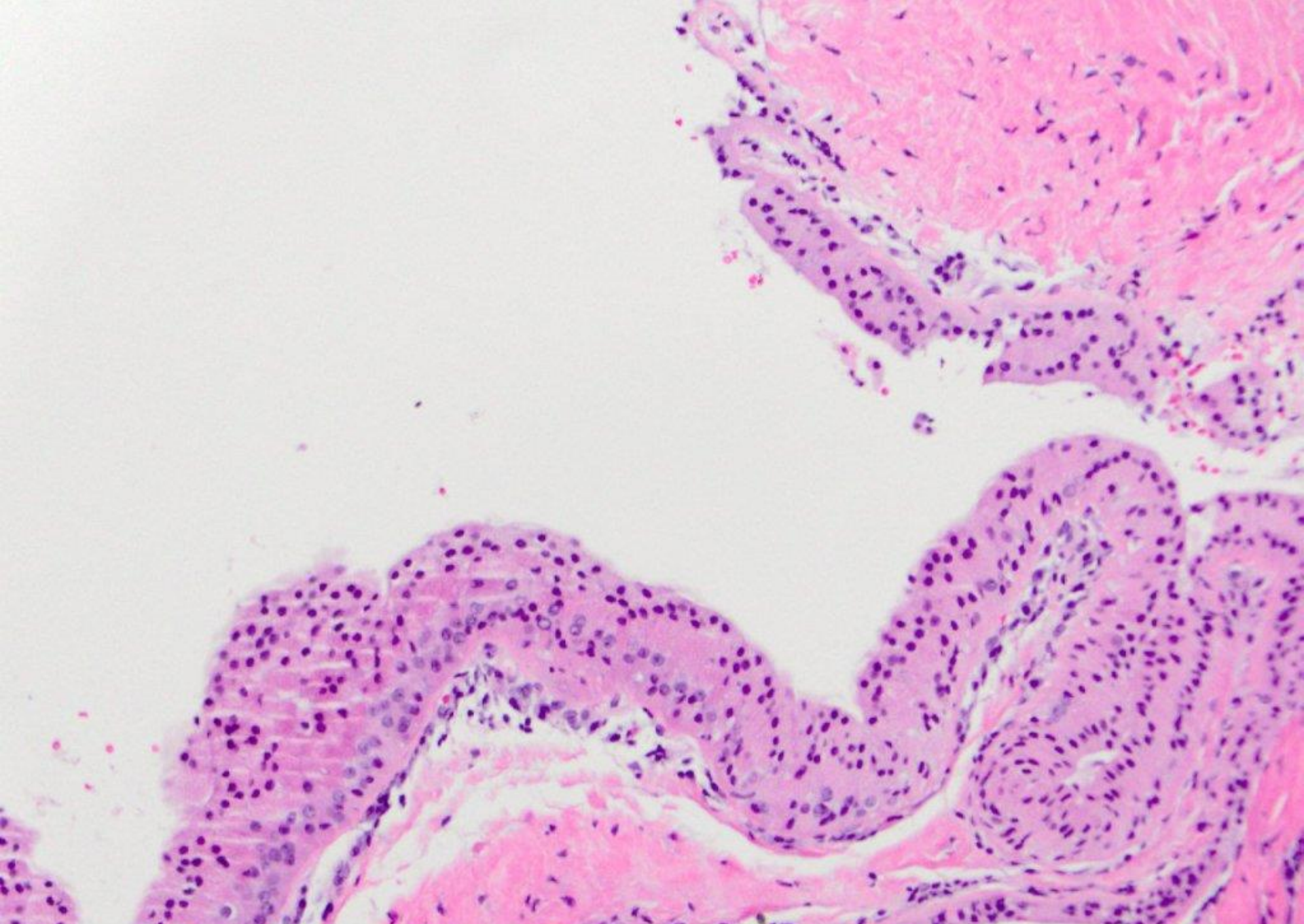
salivary duct cyst



described as being on lower lip

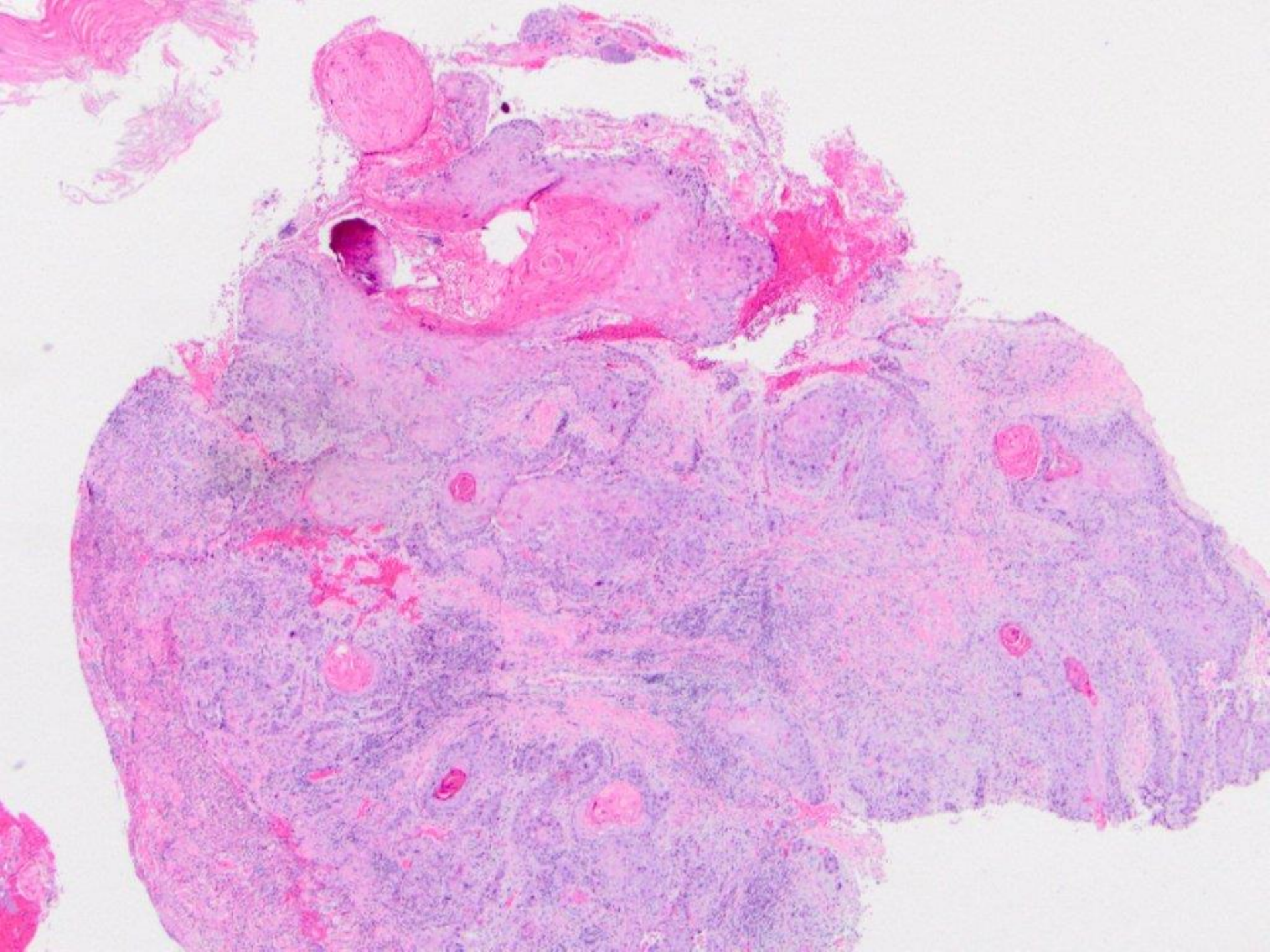




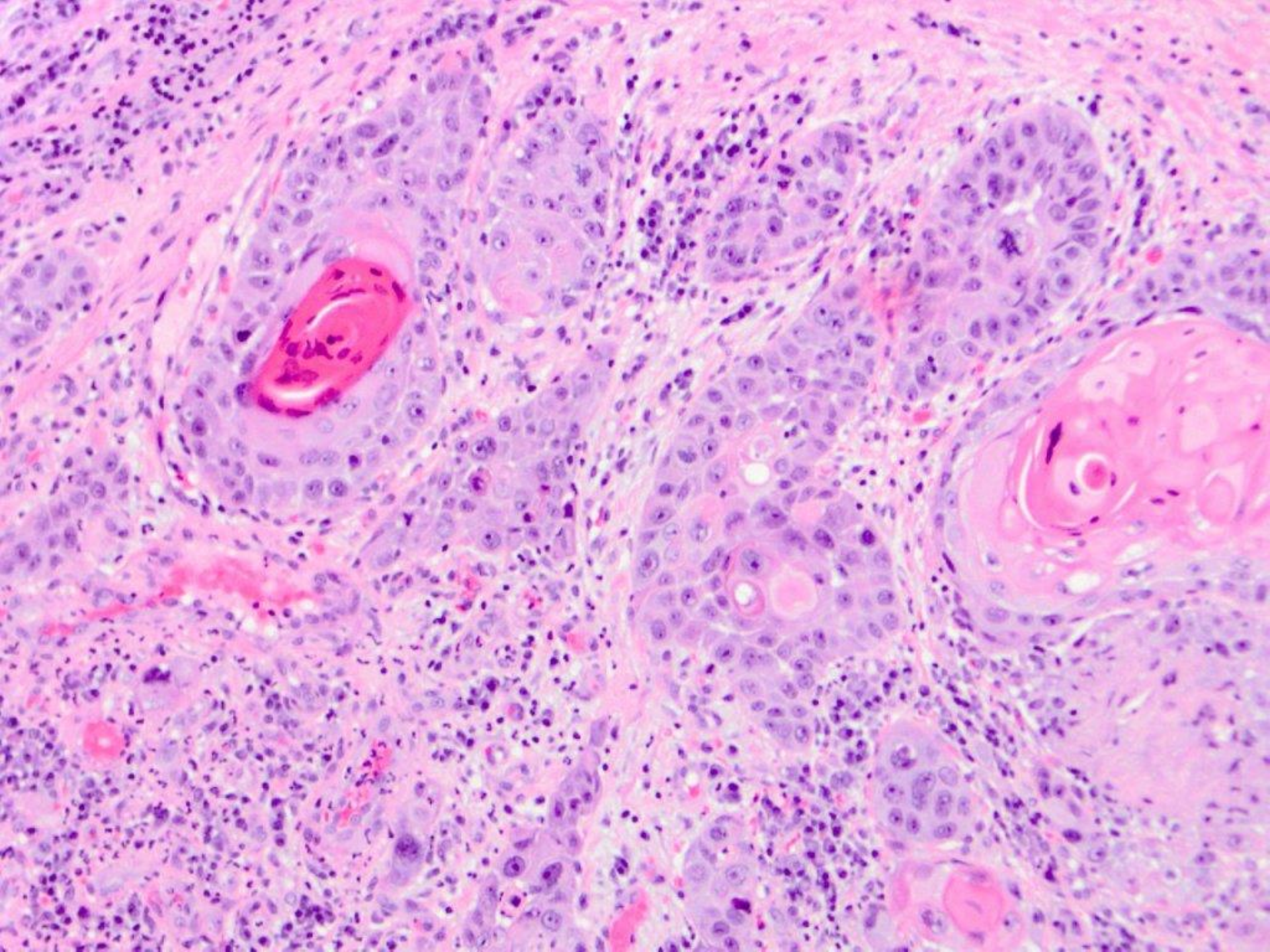


salivary duct cyst with oncocytic metaplasia

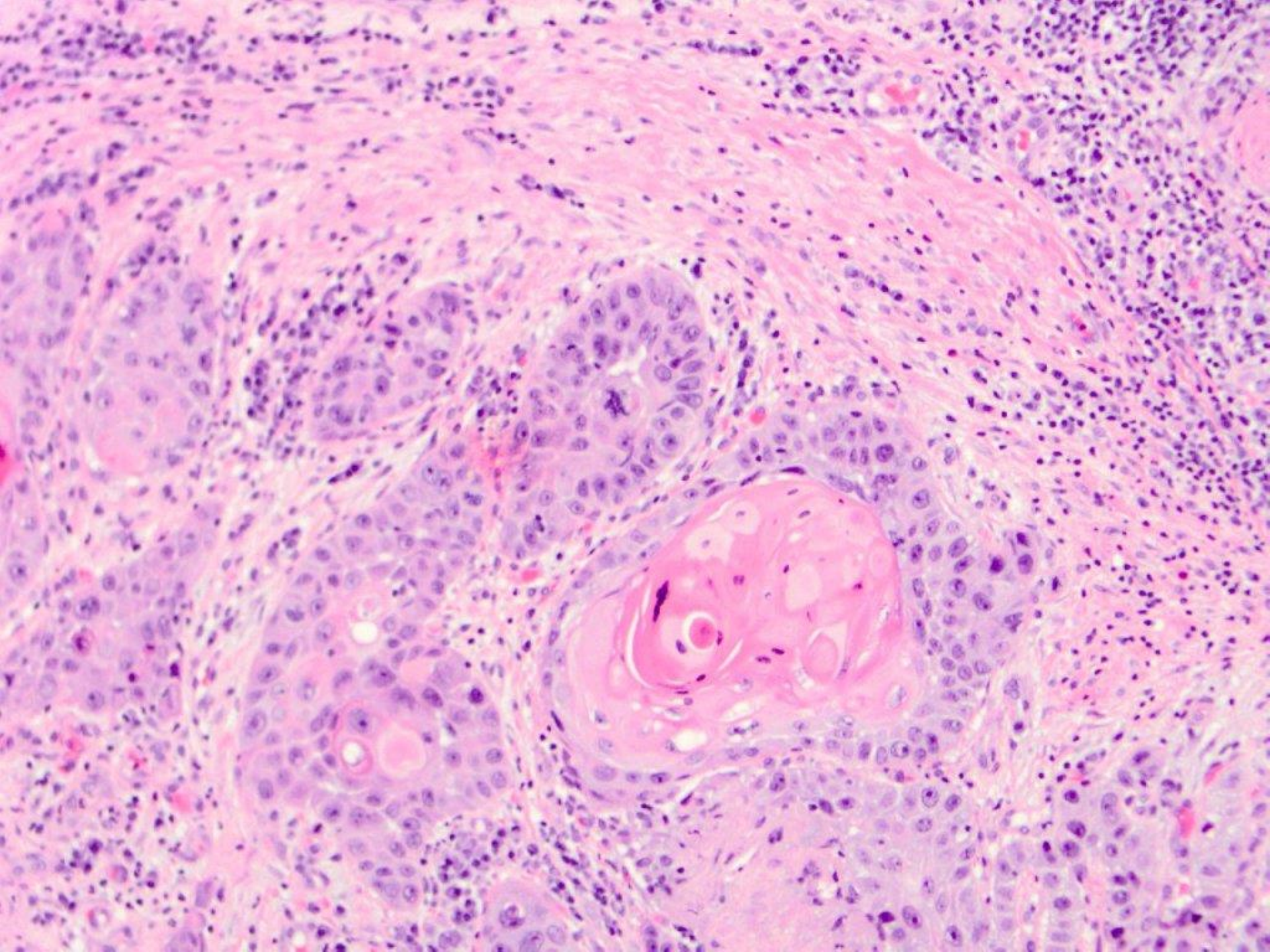




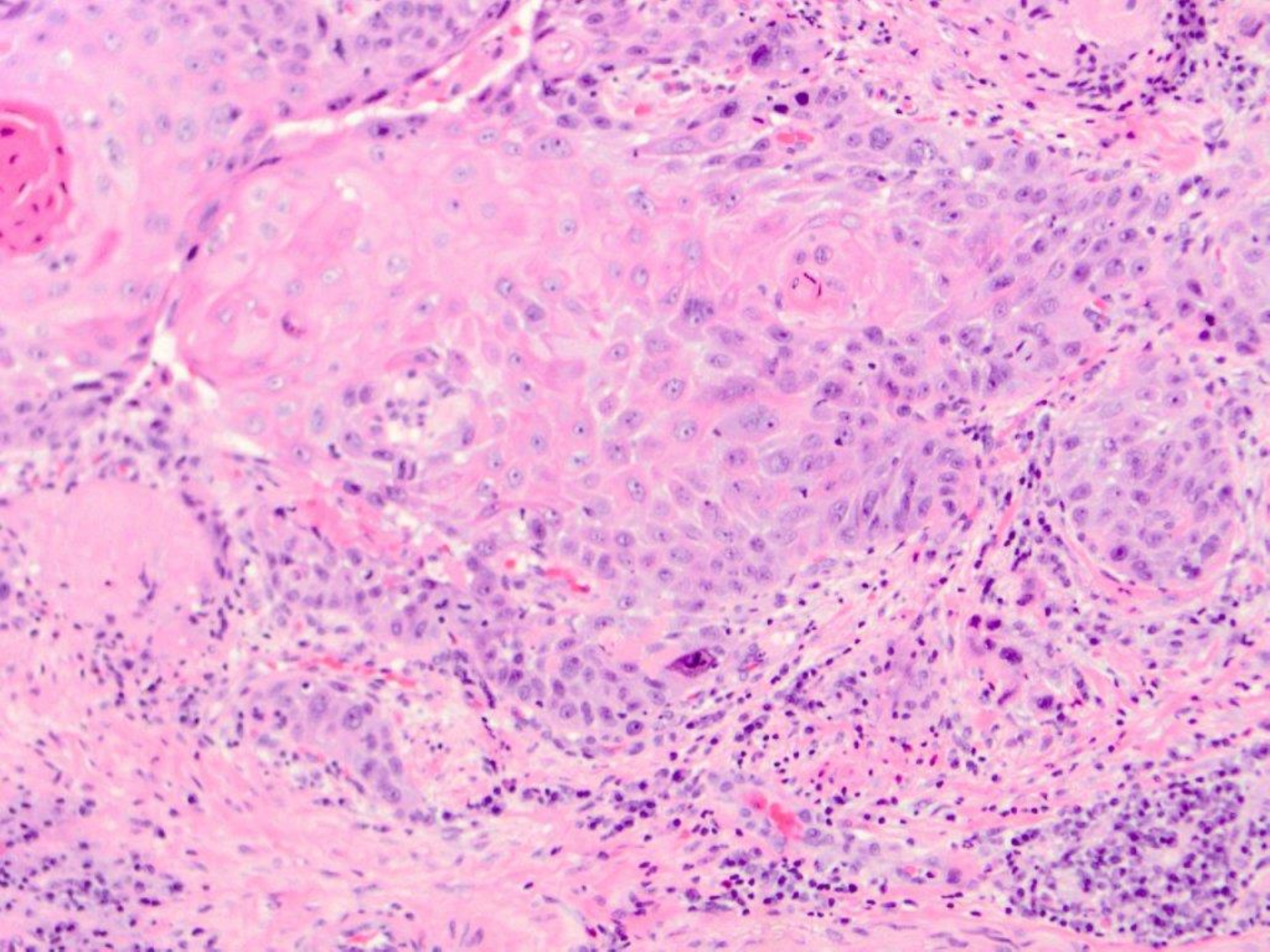




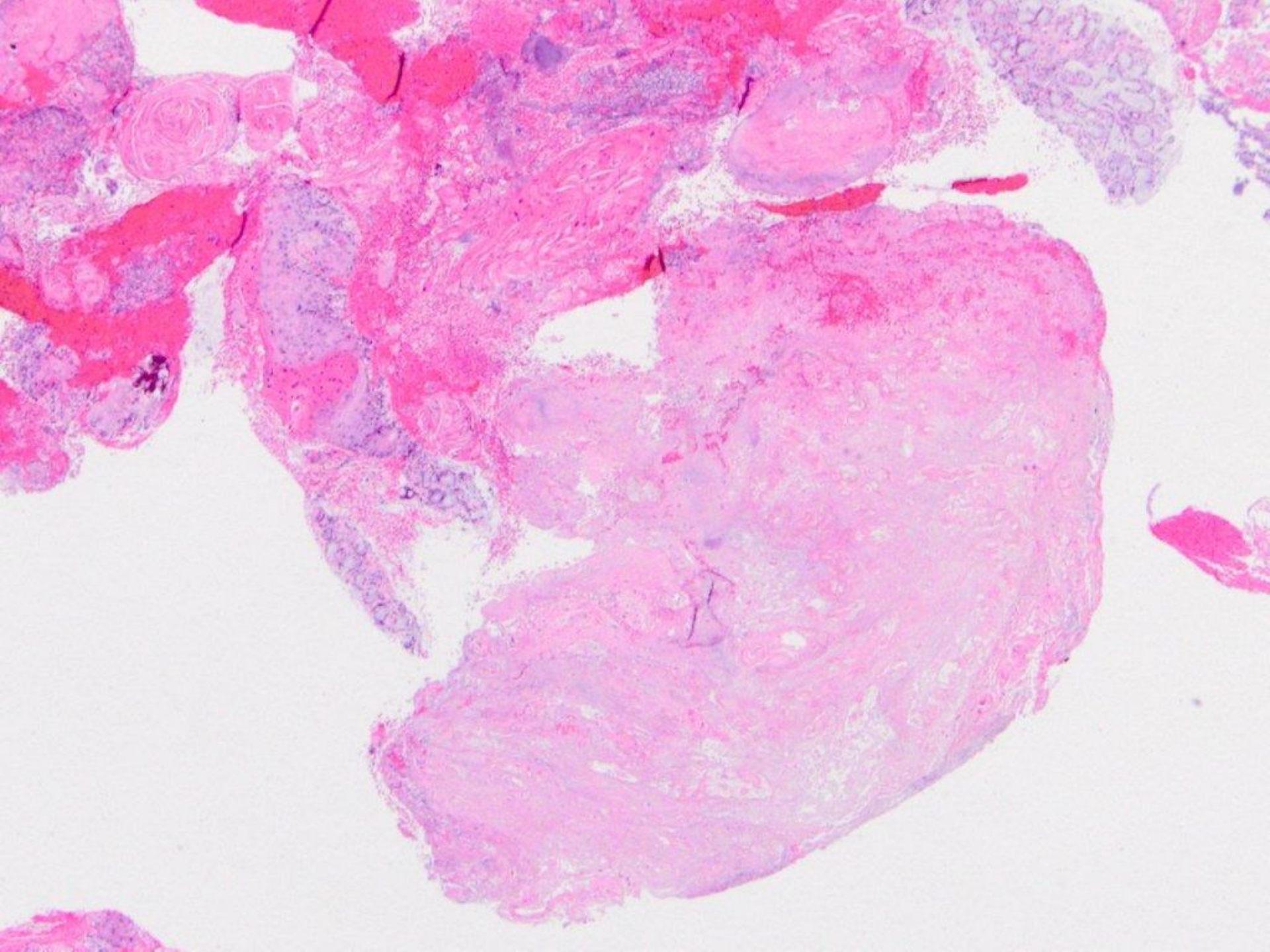




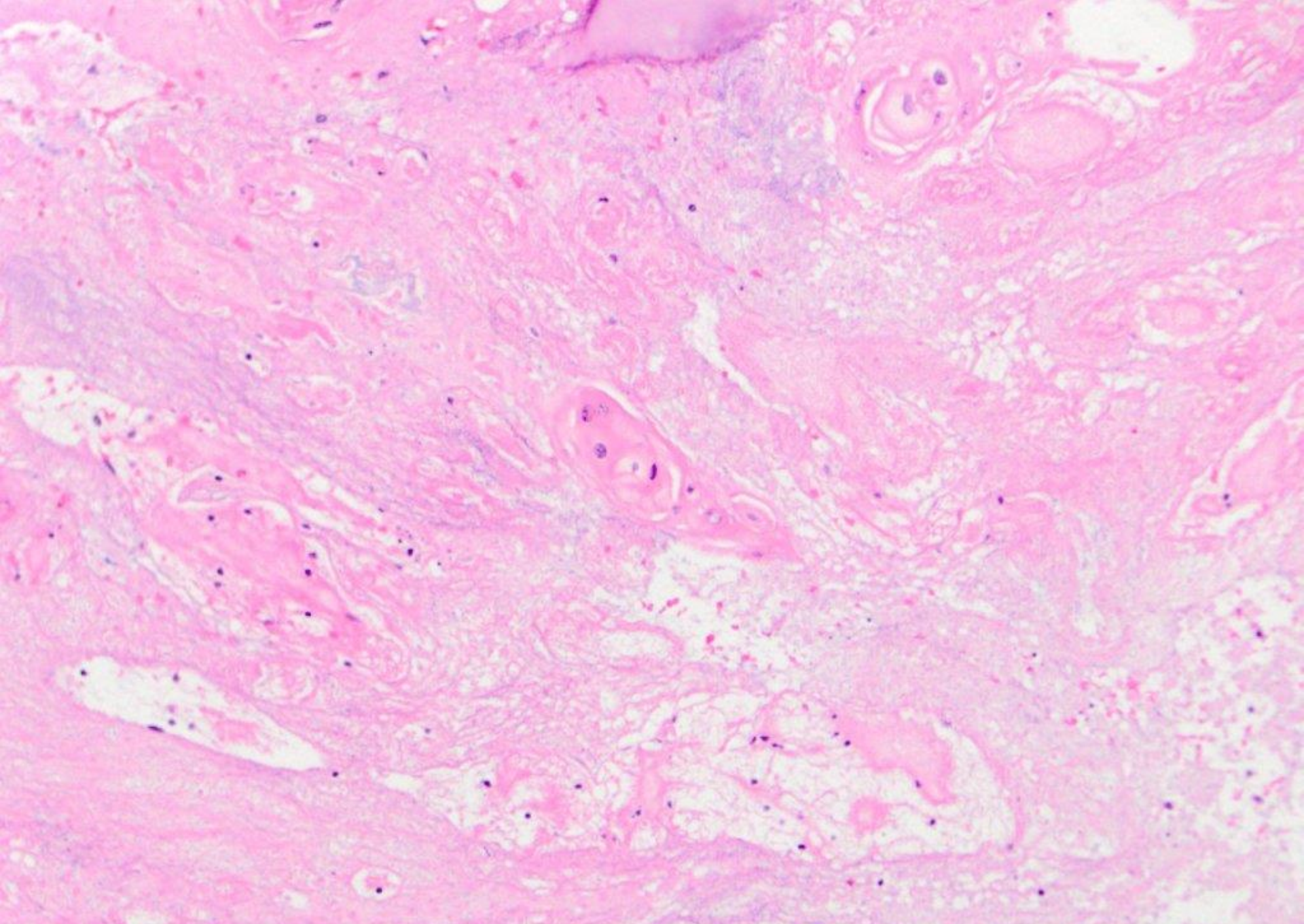






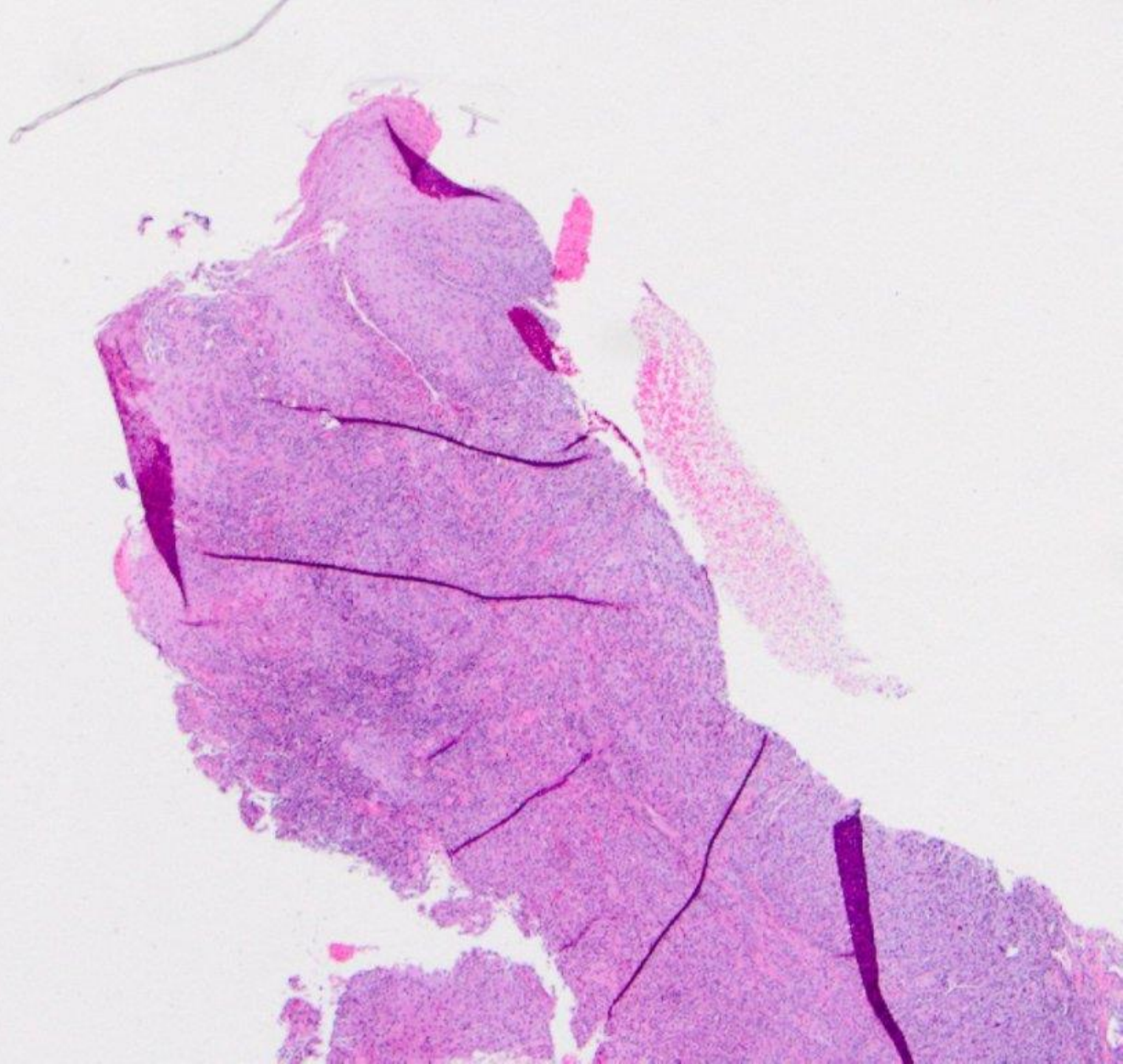




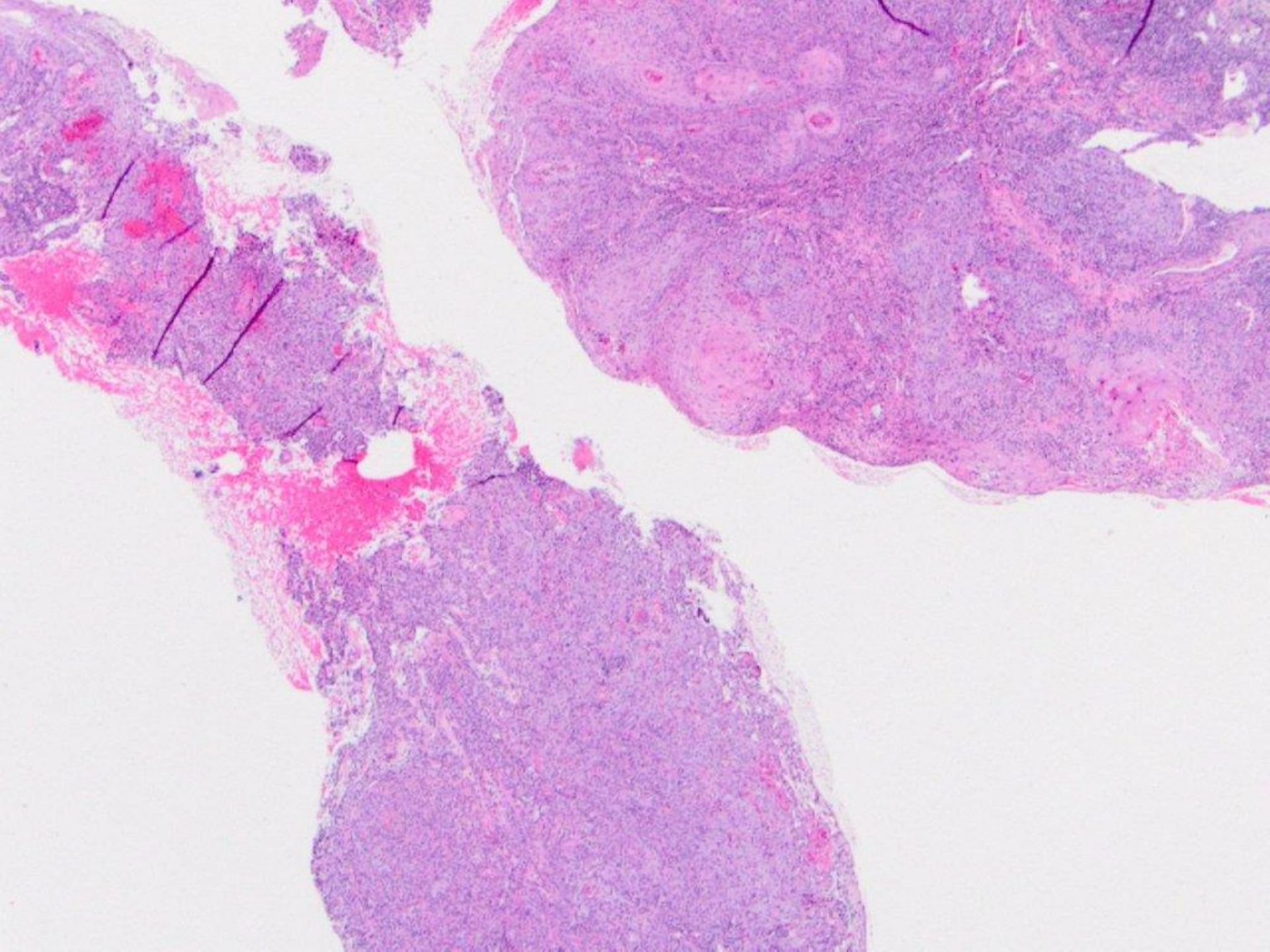


squamous cell carcinoma (with necrosis)

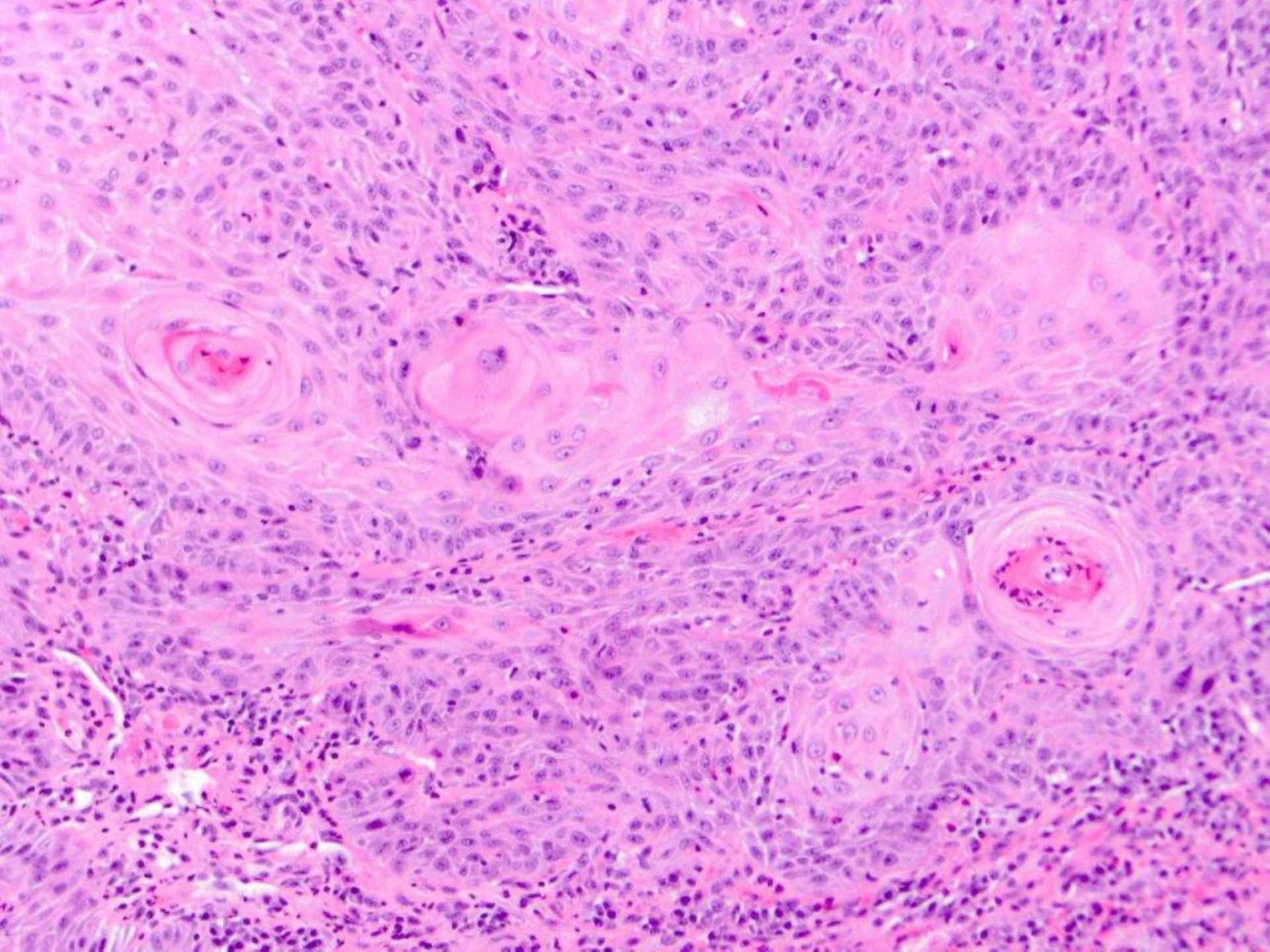




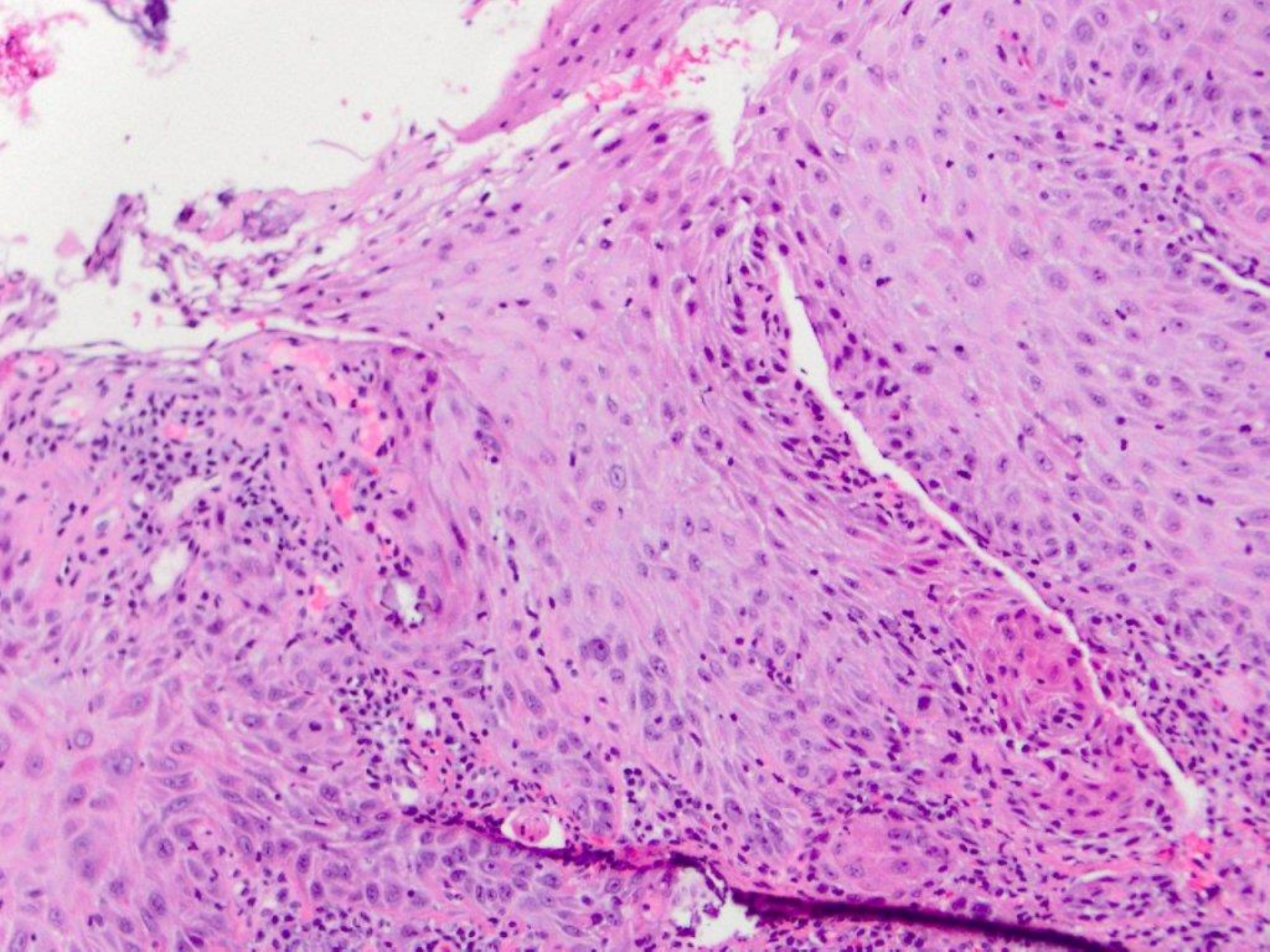




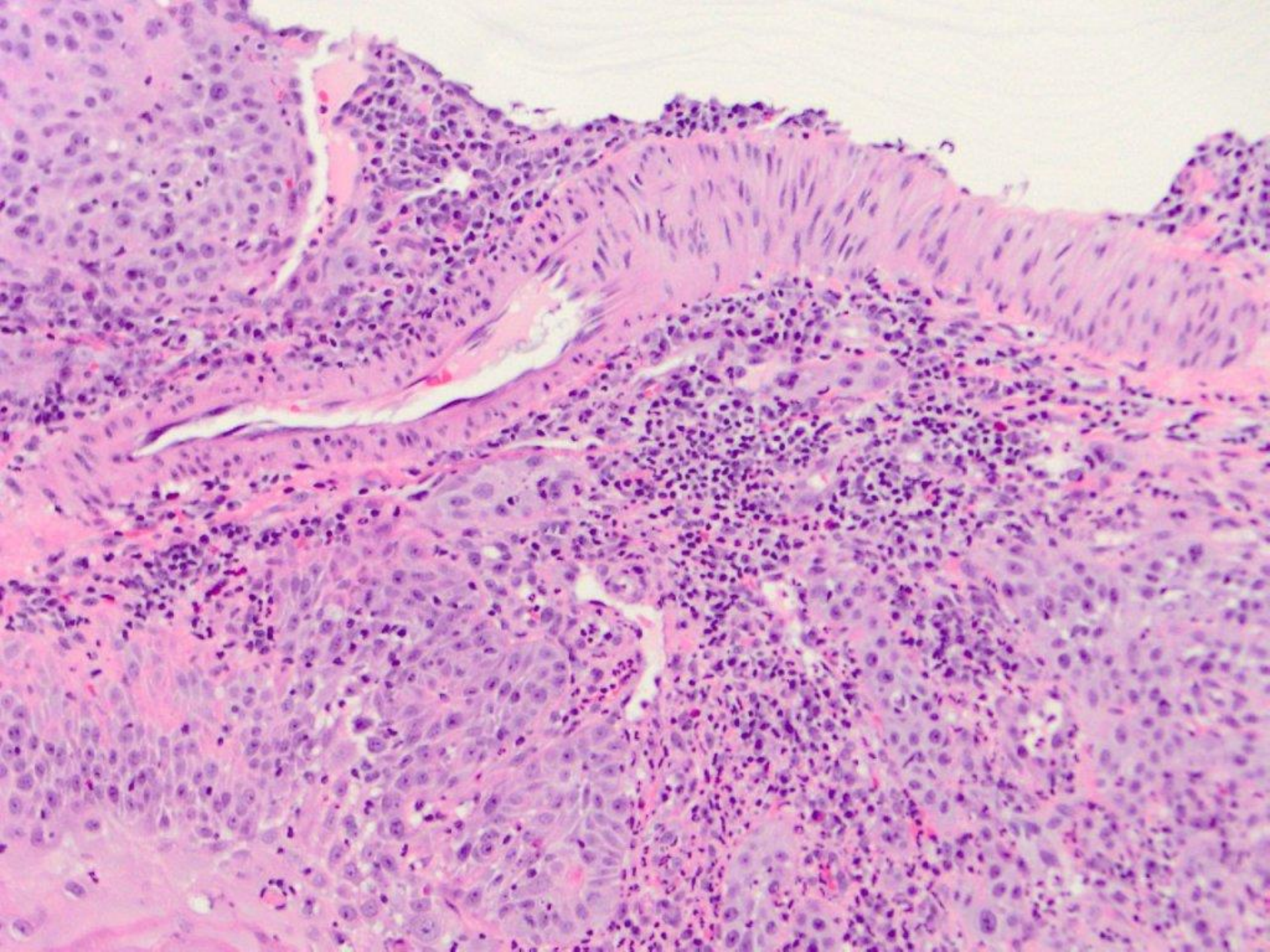




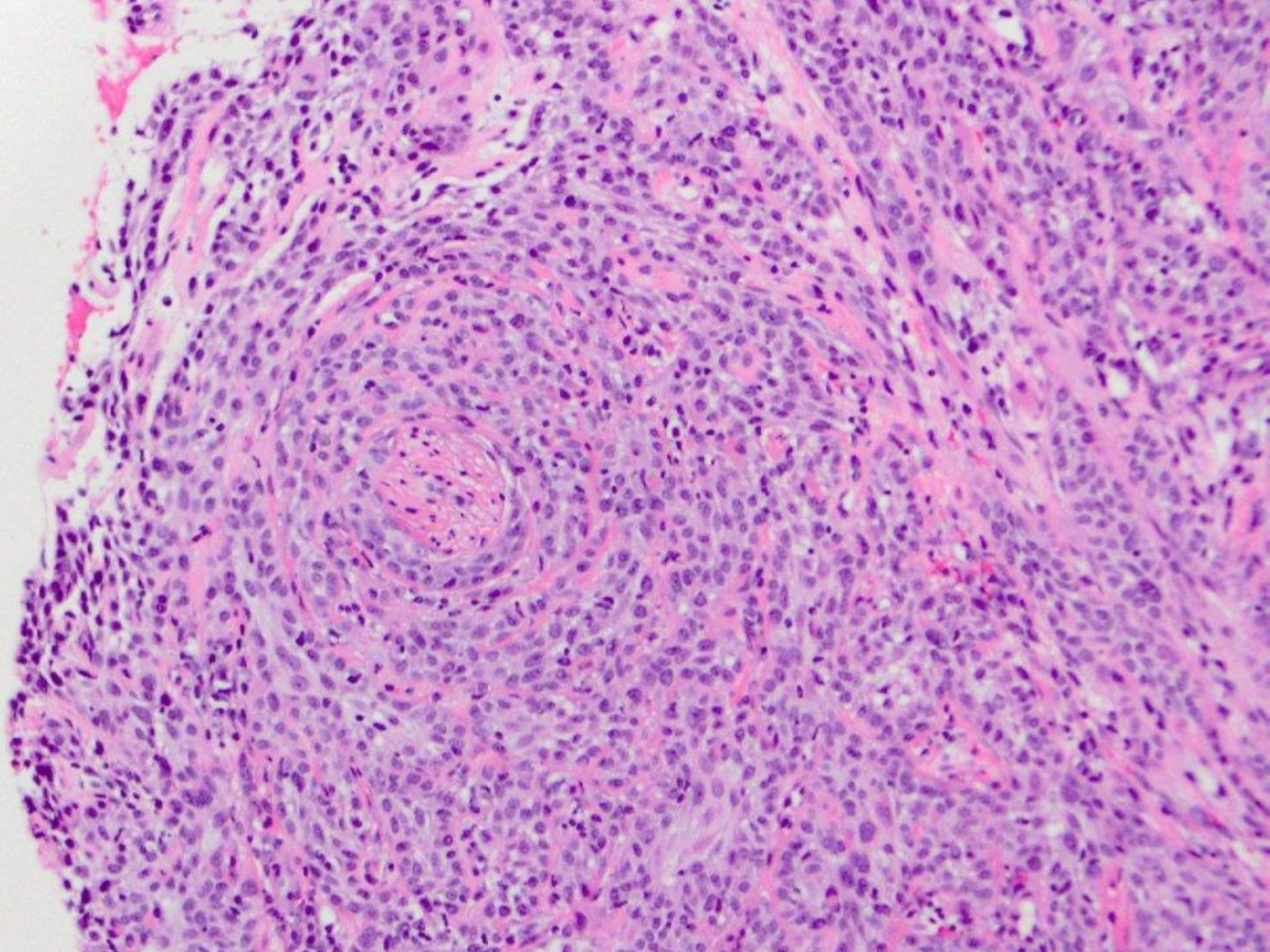






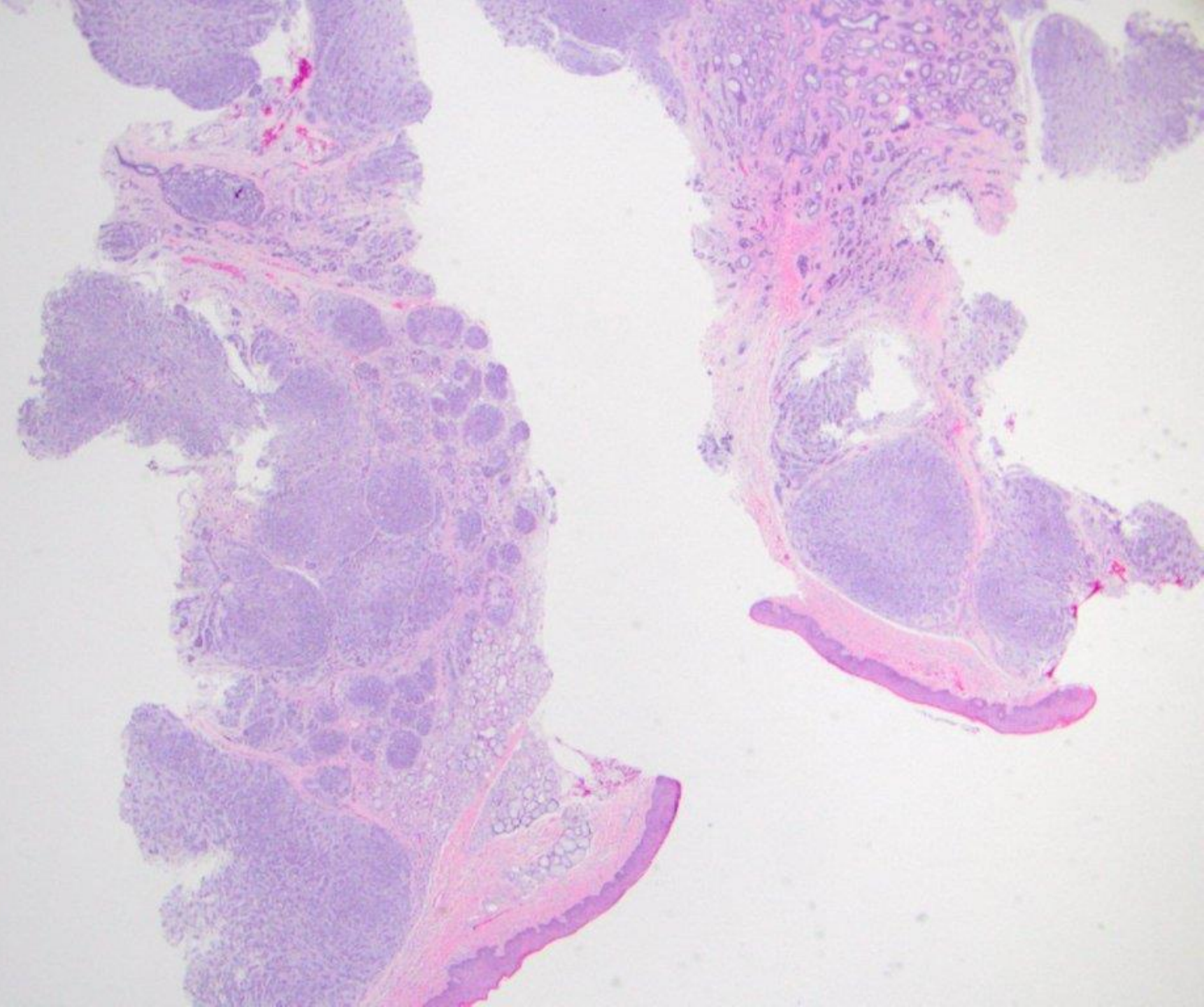




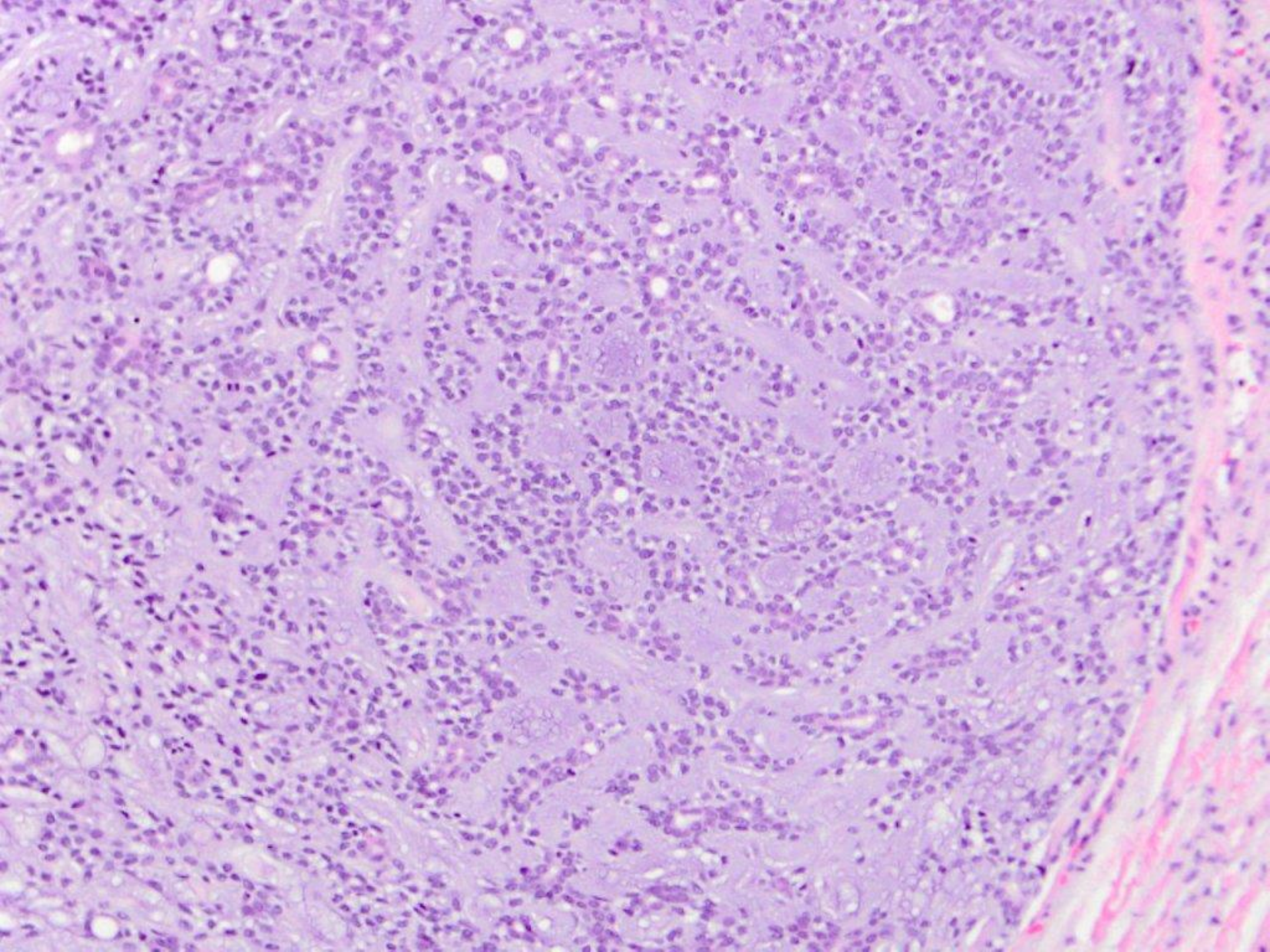


squamous cell carcinoma (with perineural and perivascular invasion)

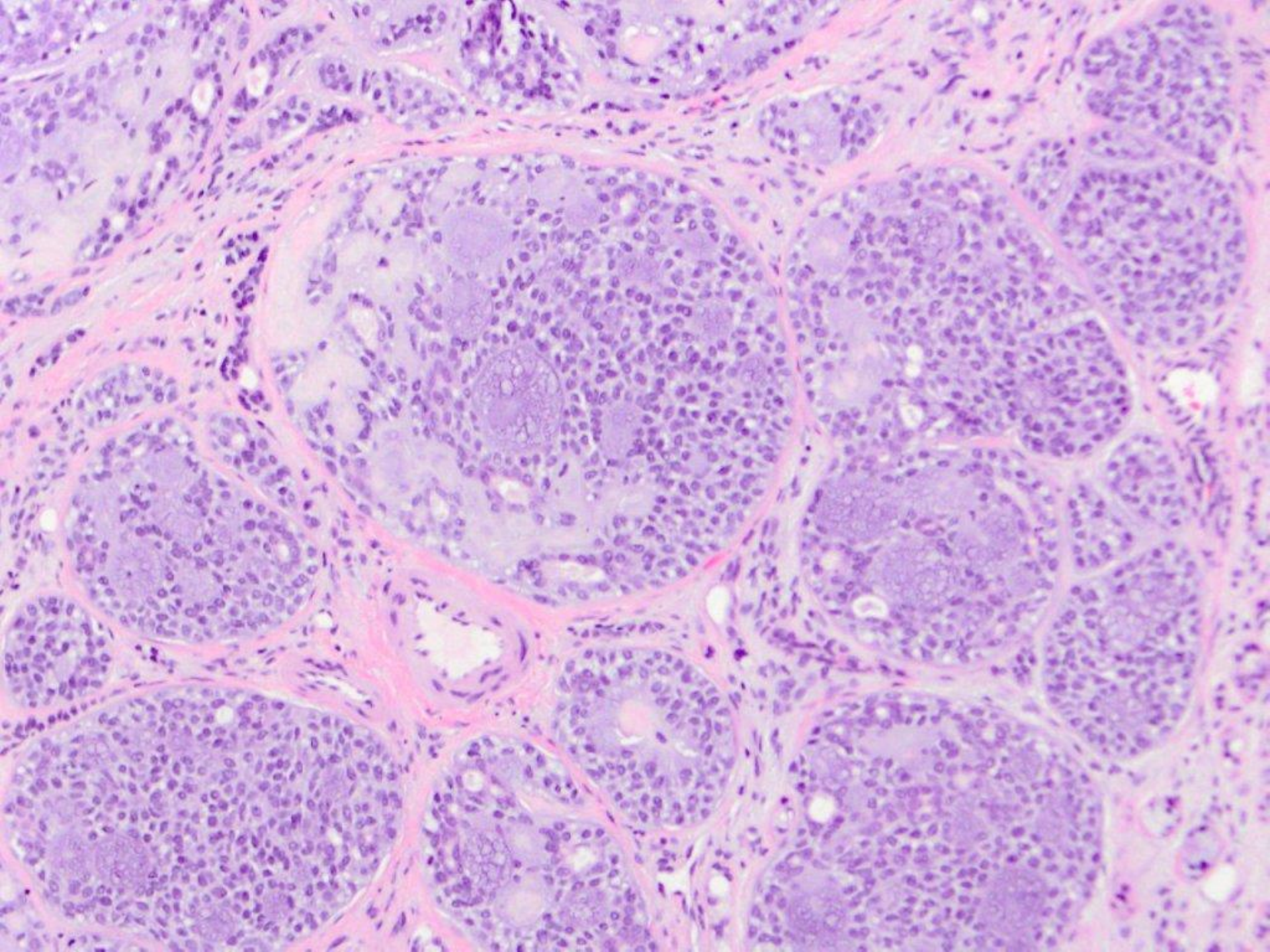




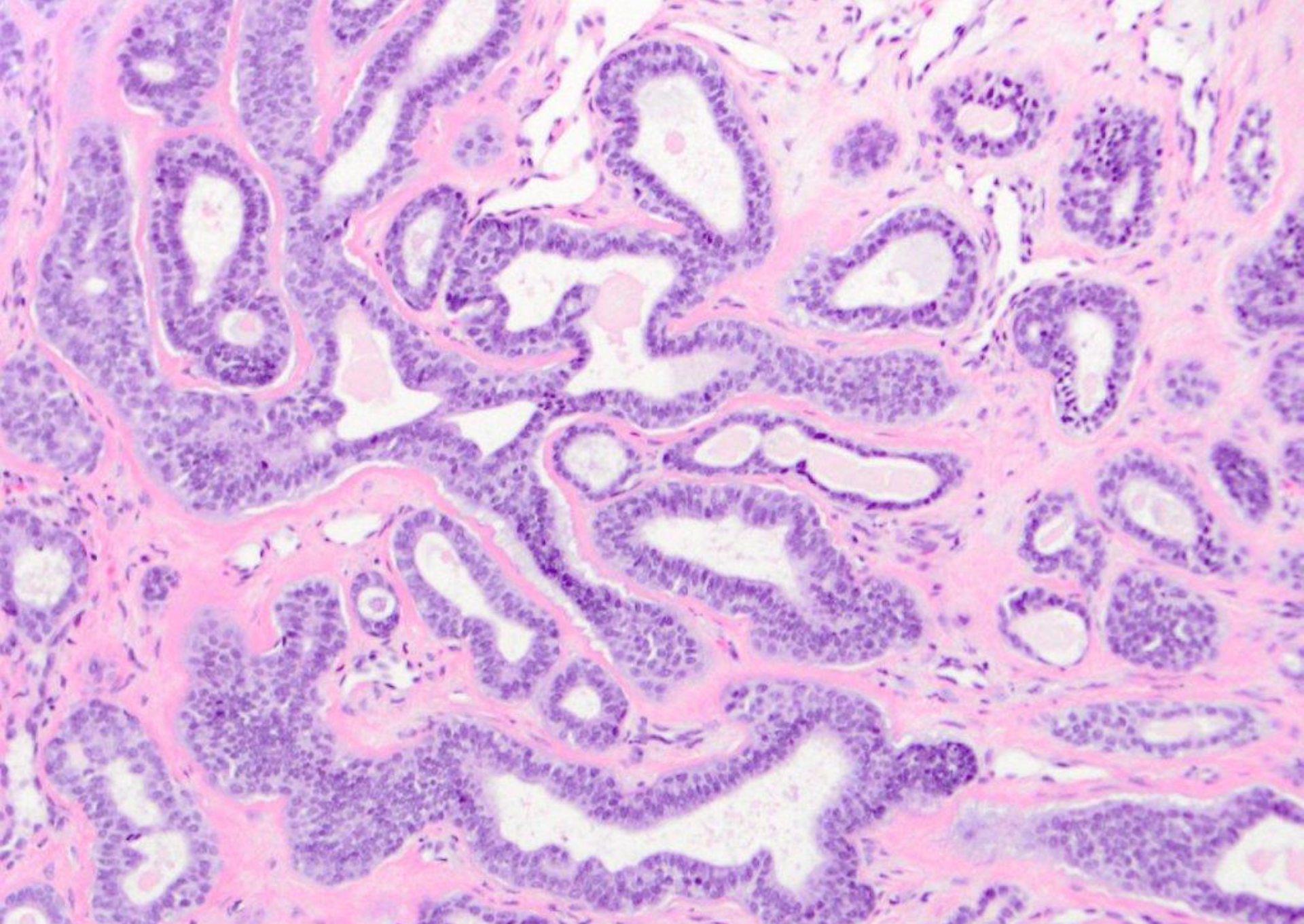






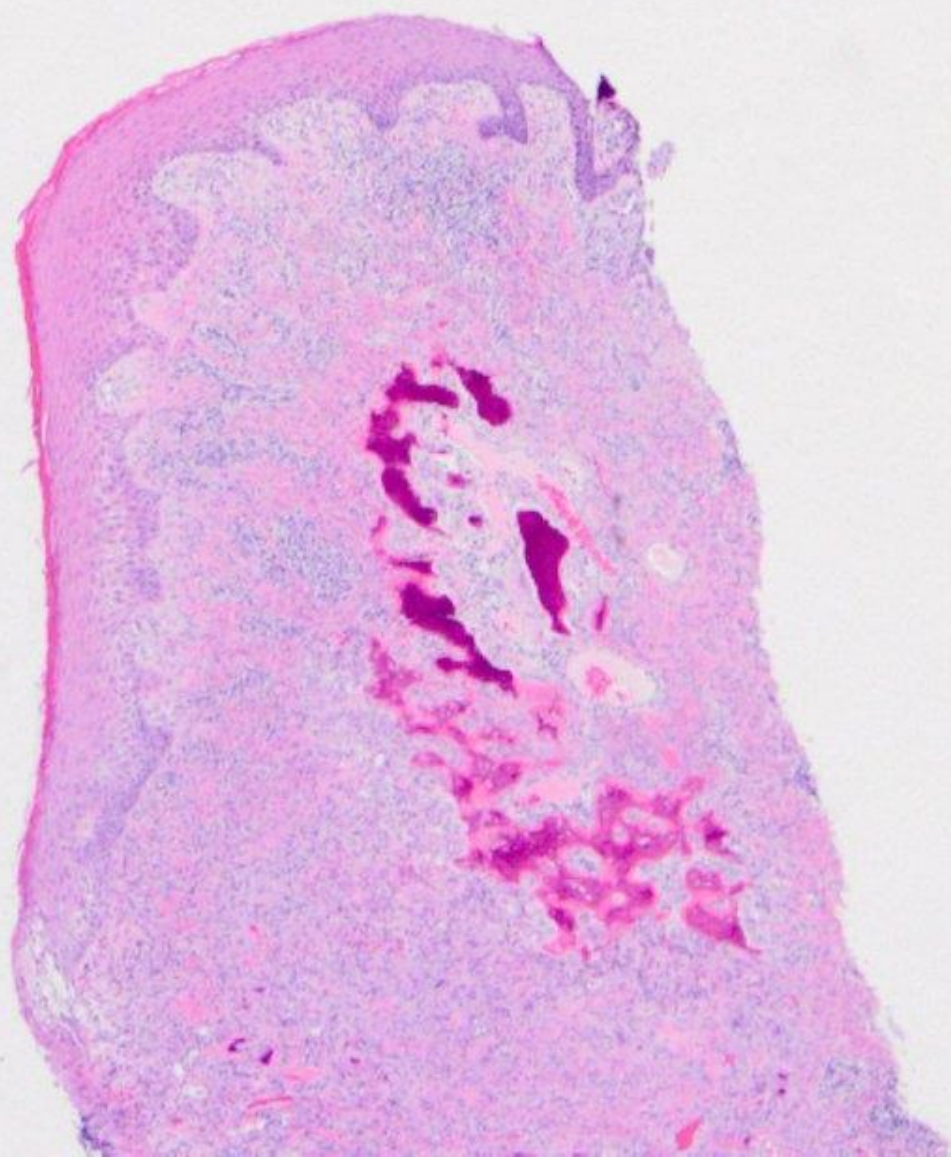




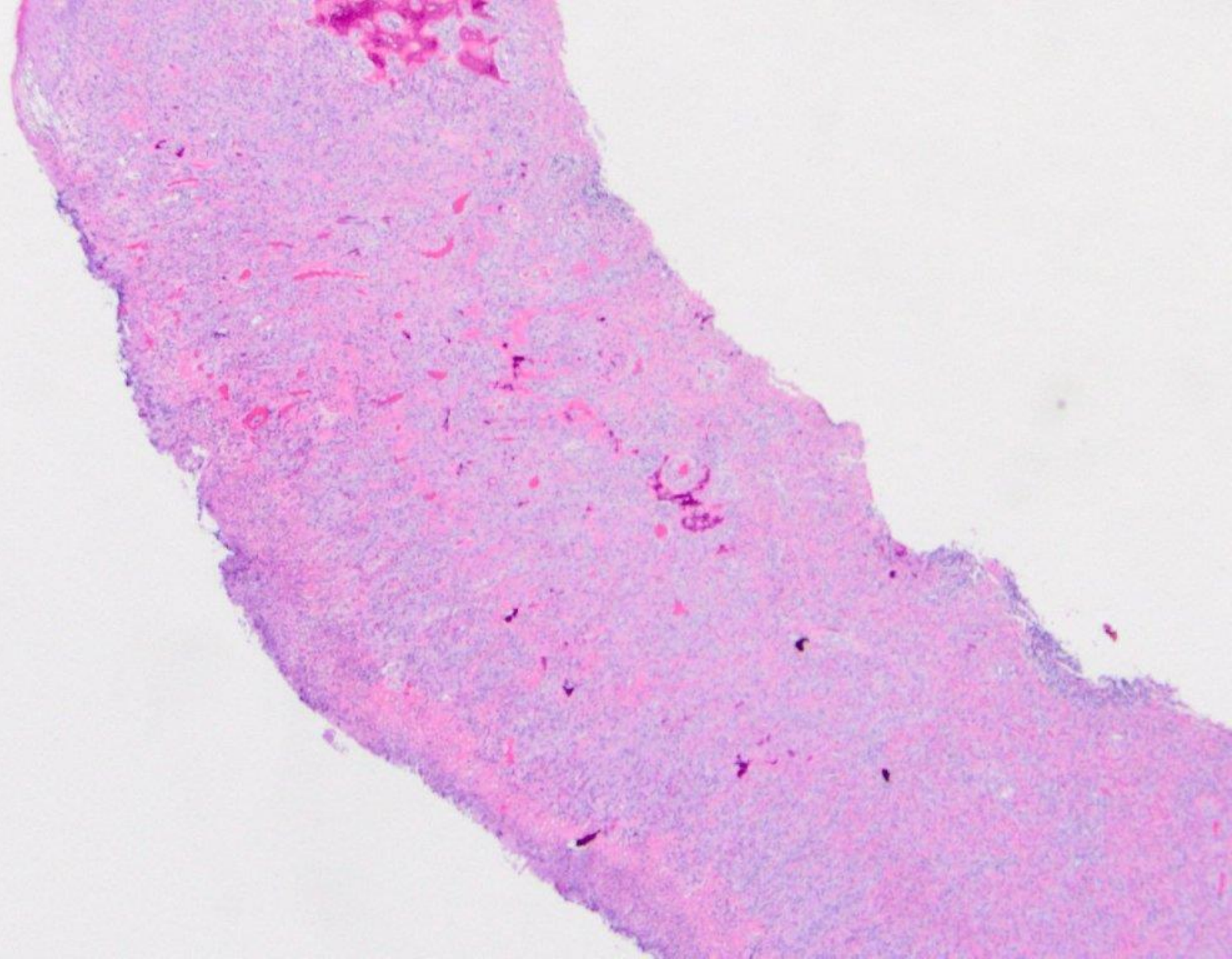


adenoid cystic carcinoma

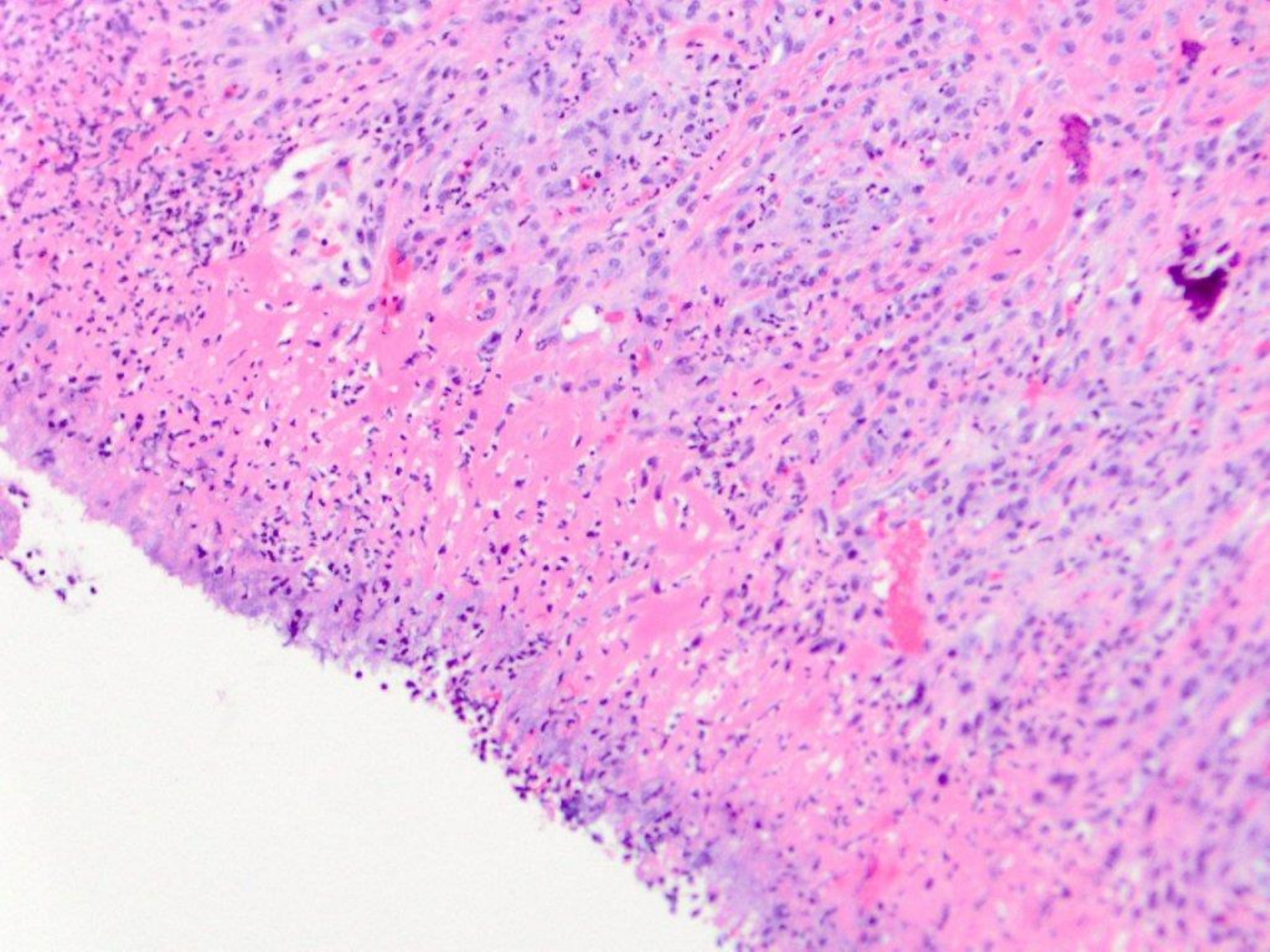




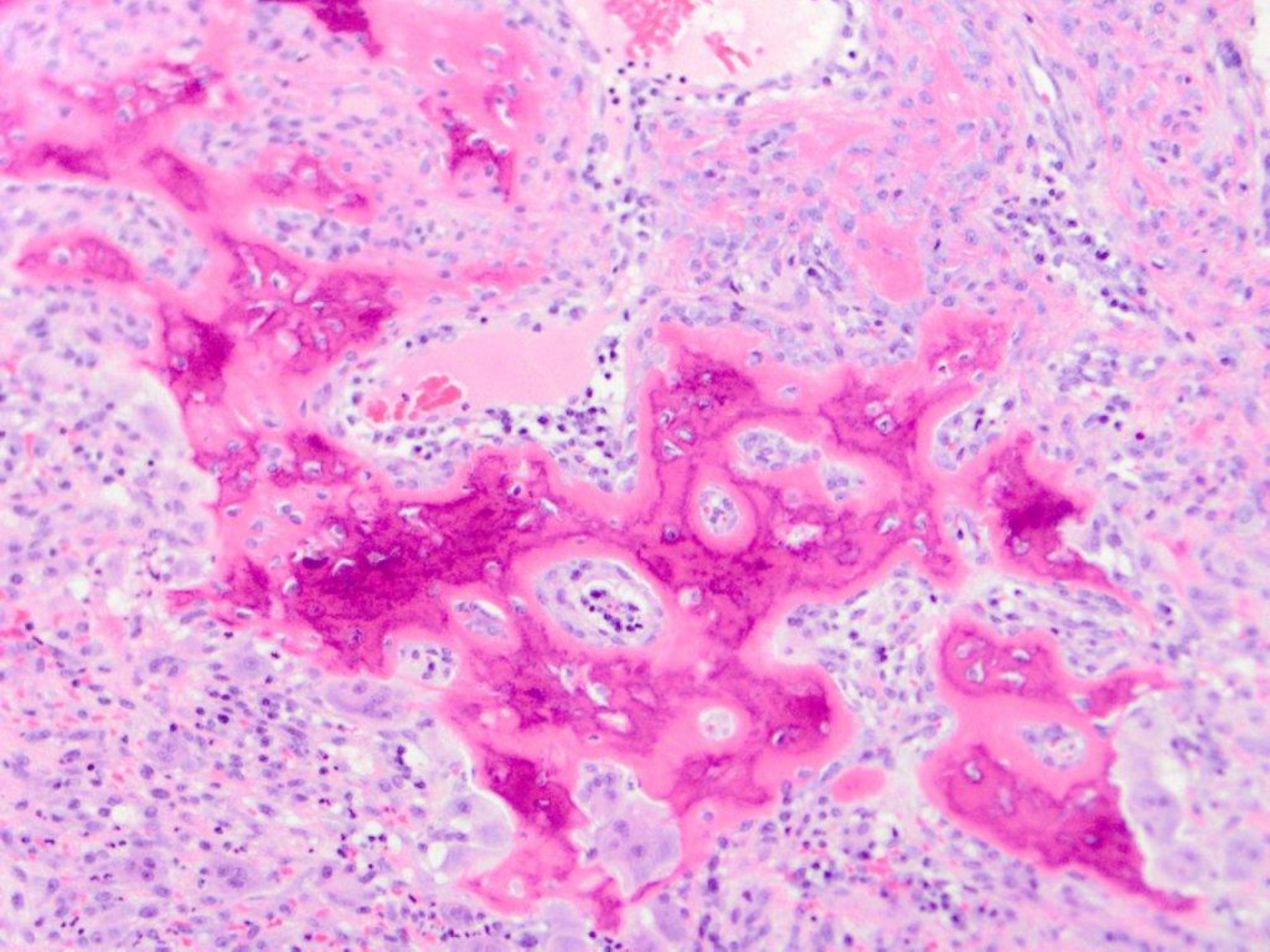




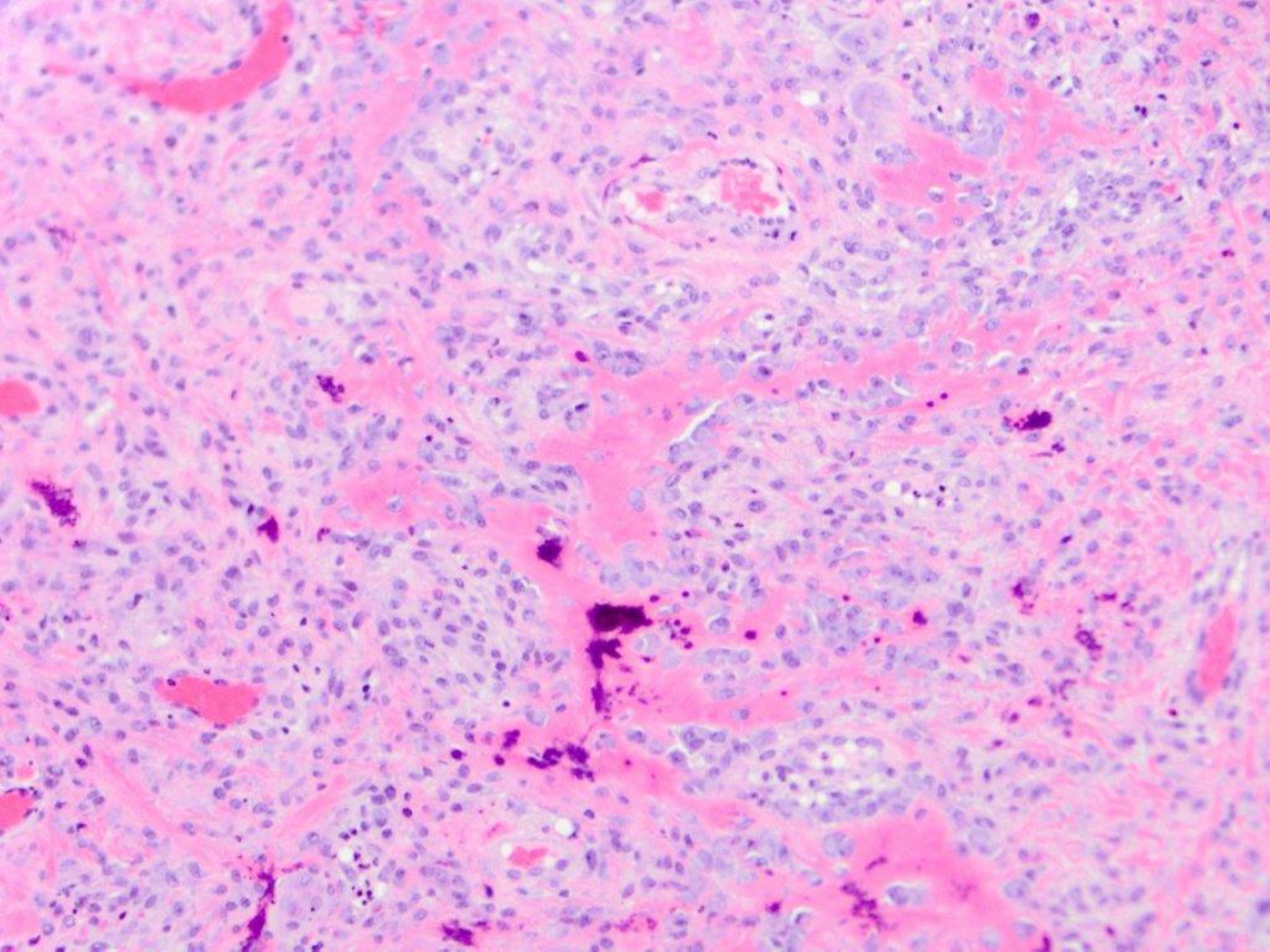




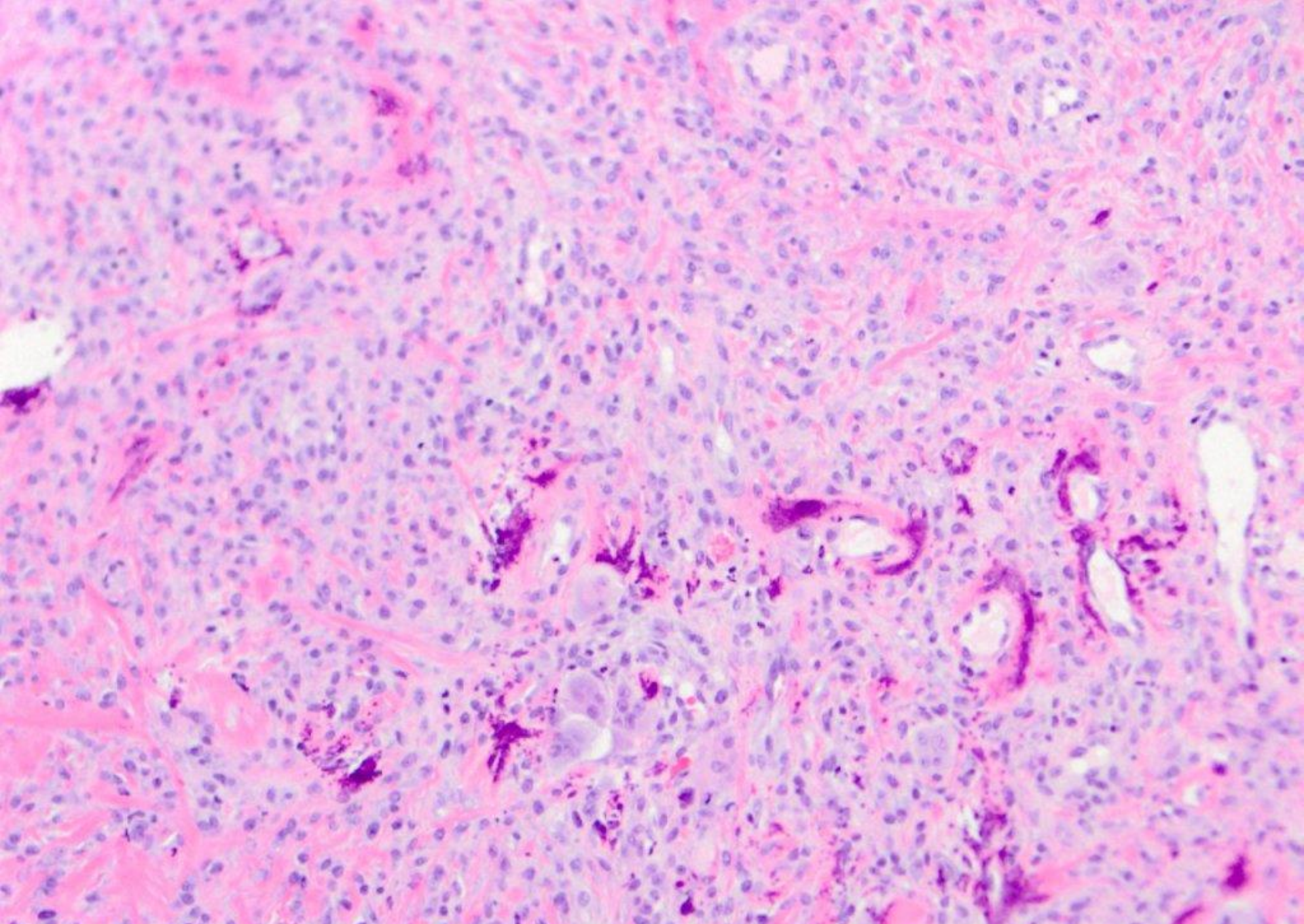






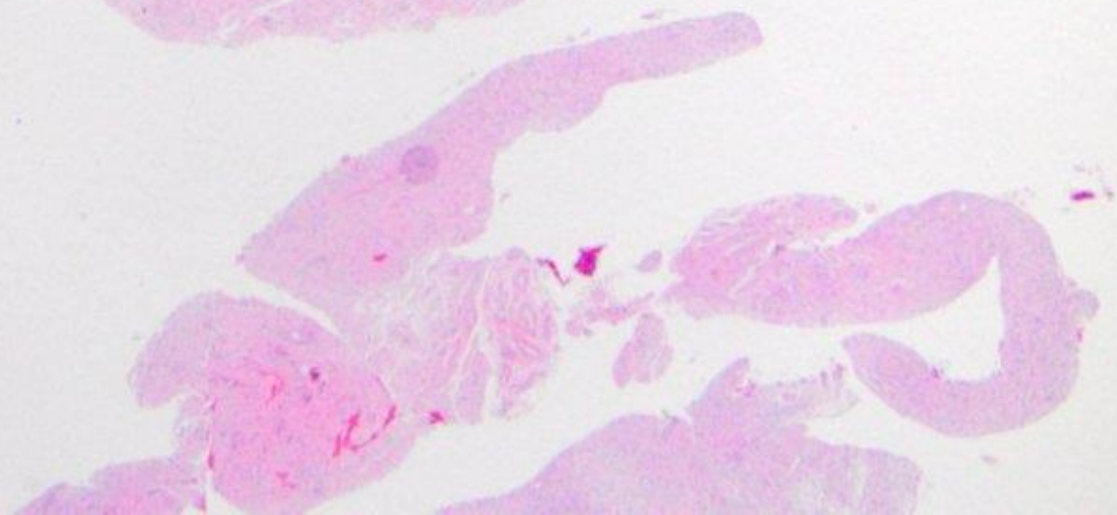
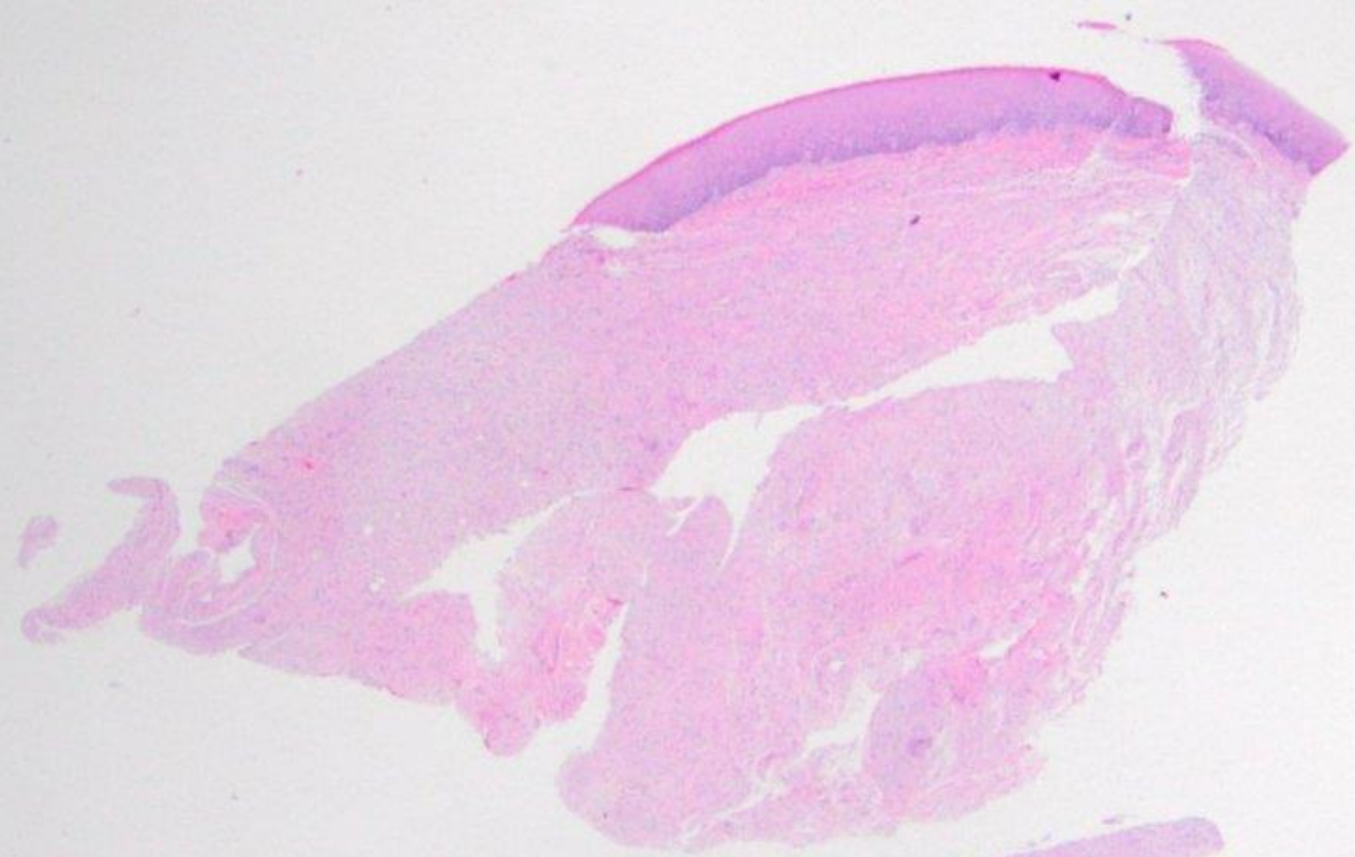




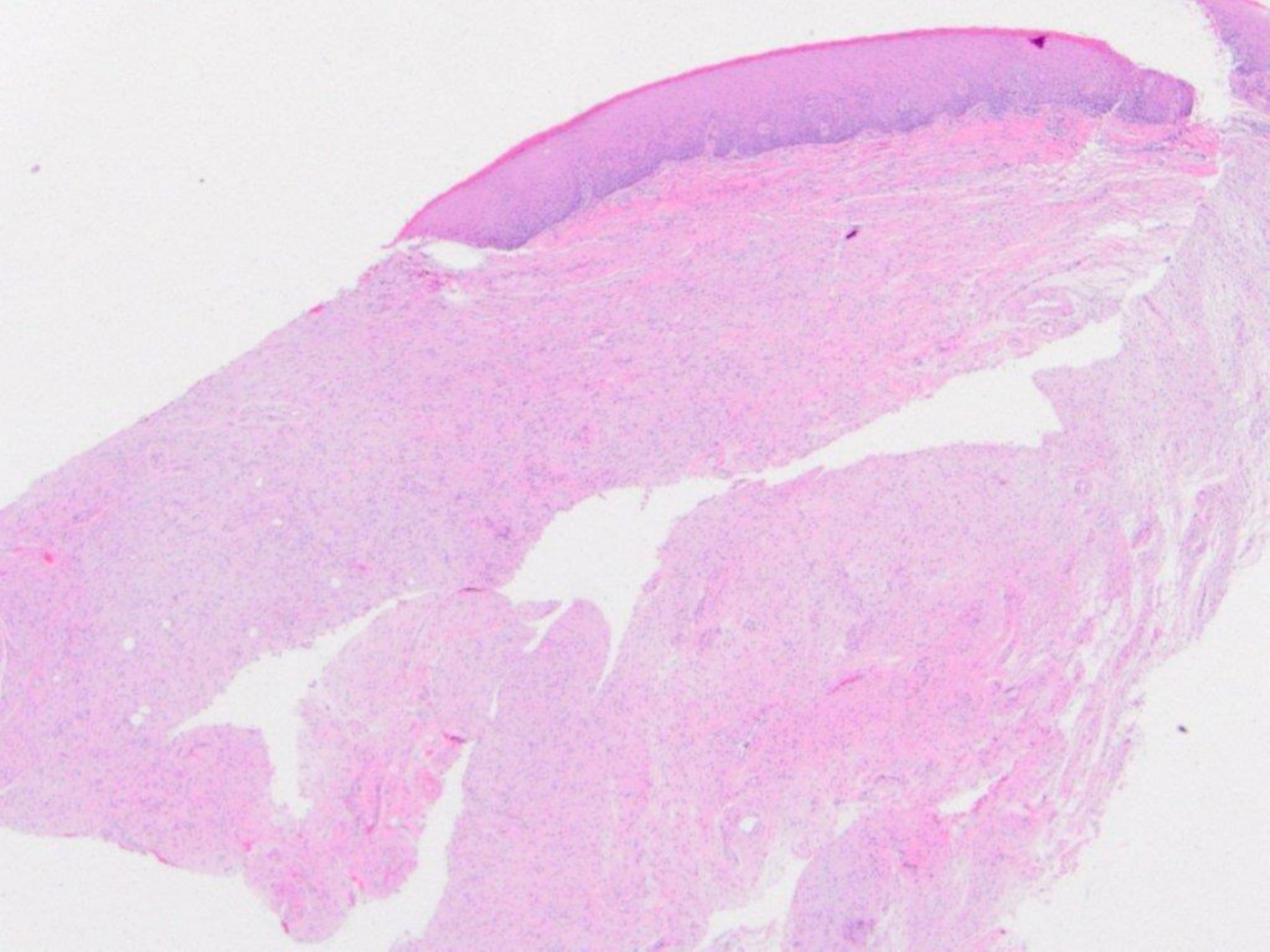


ulcerated peripheral ossifying fibroma (with giant cells)

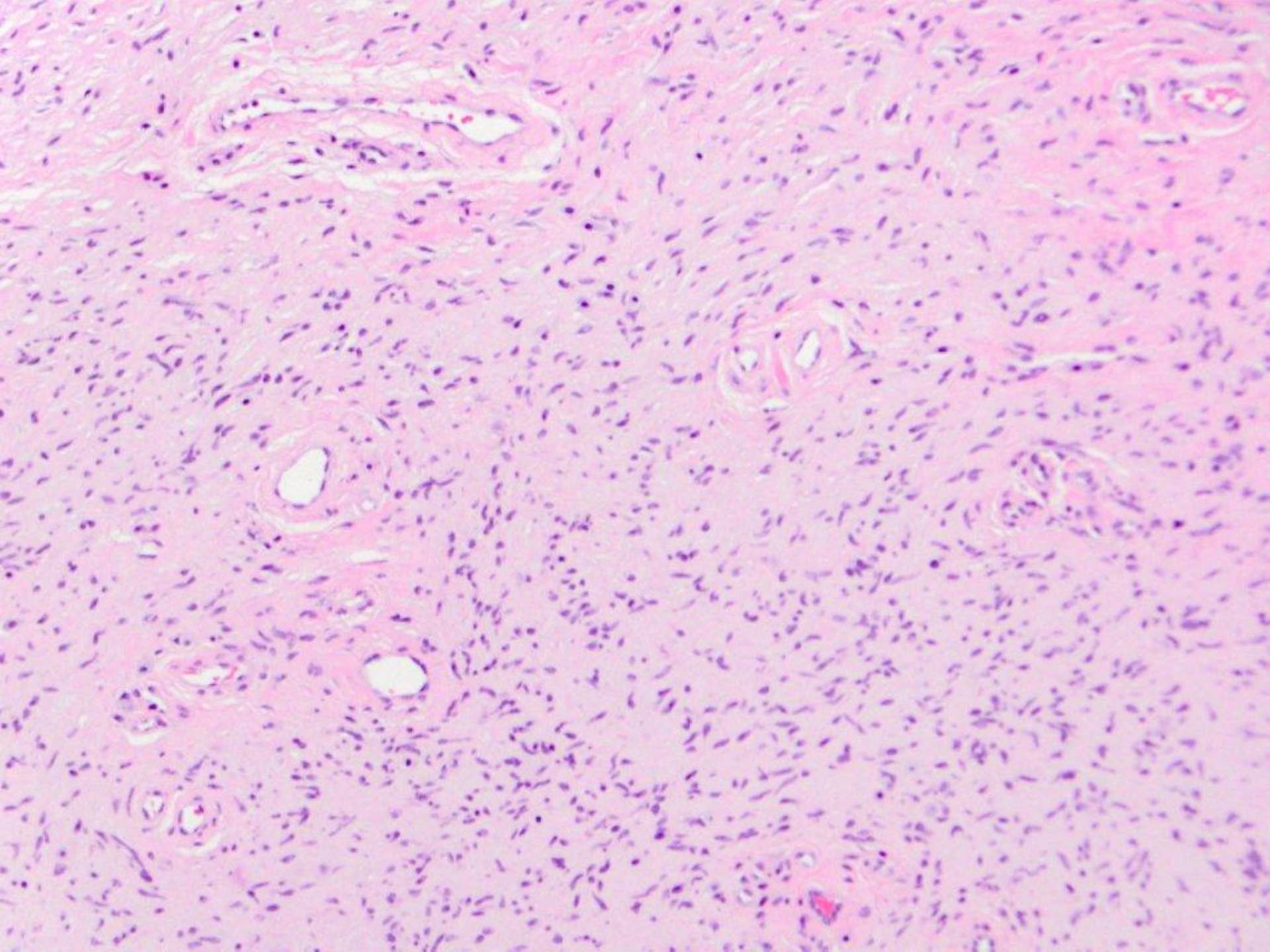




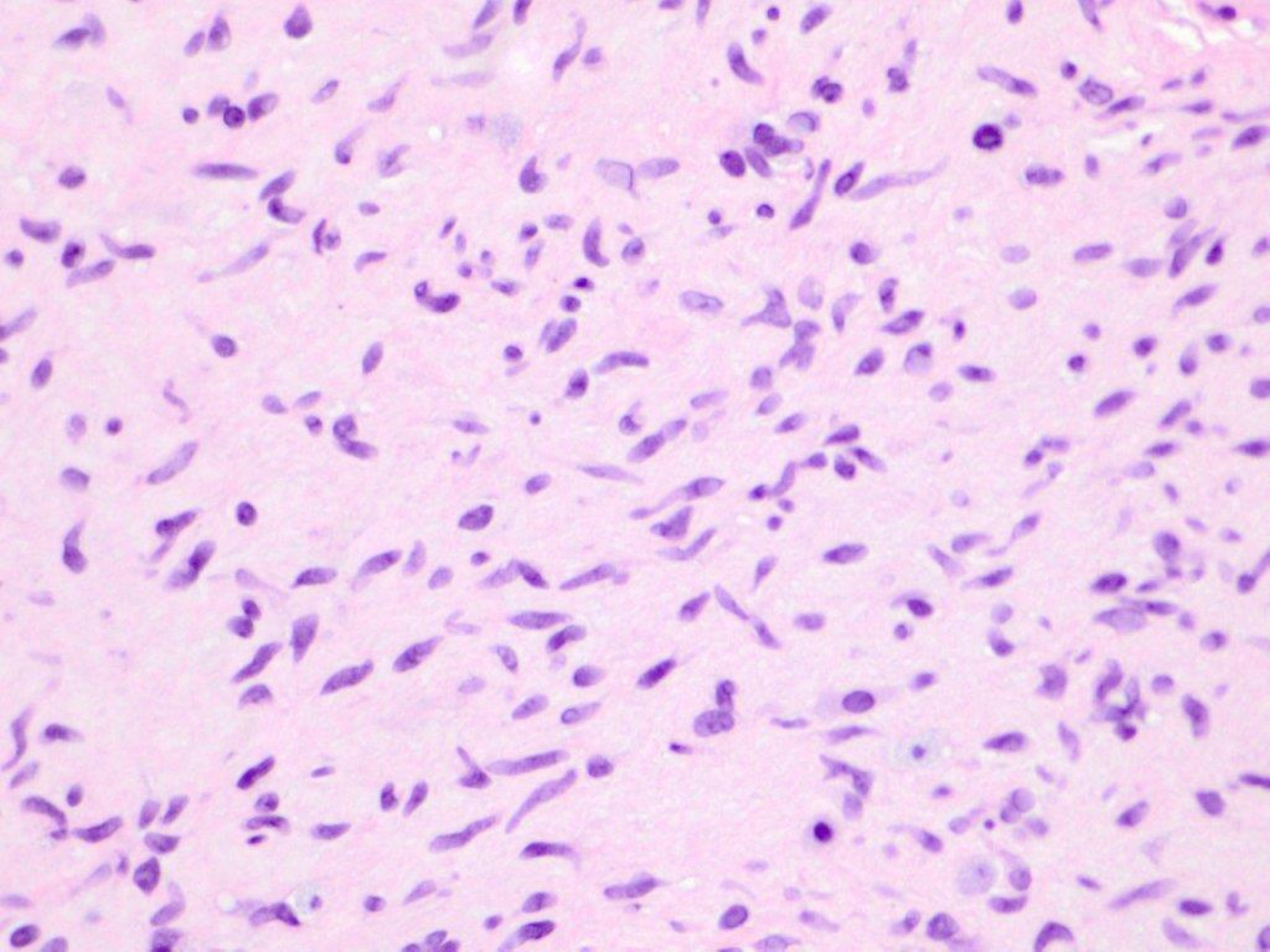




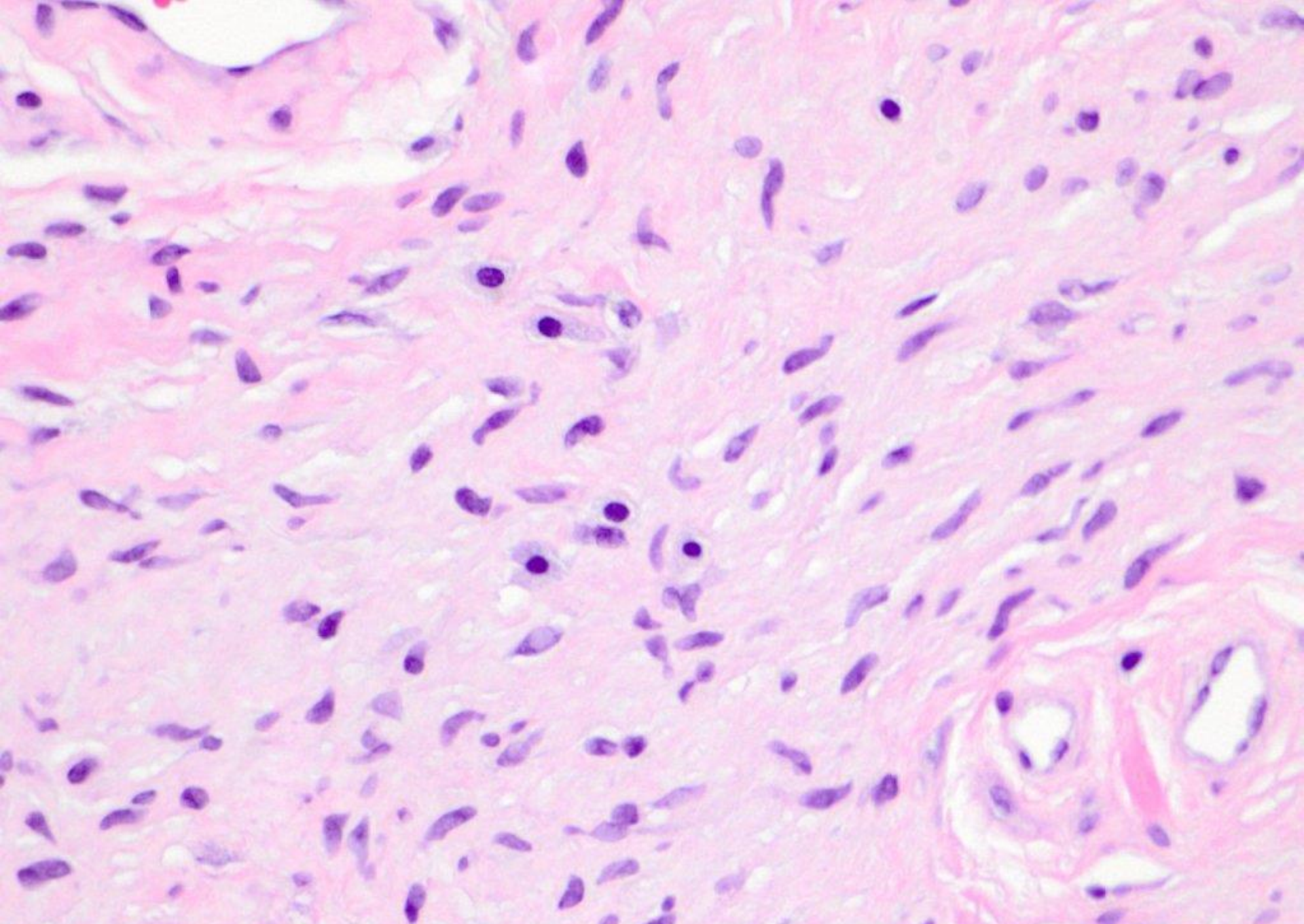








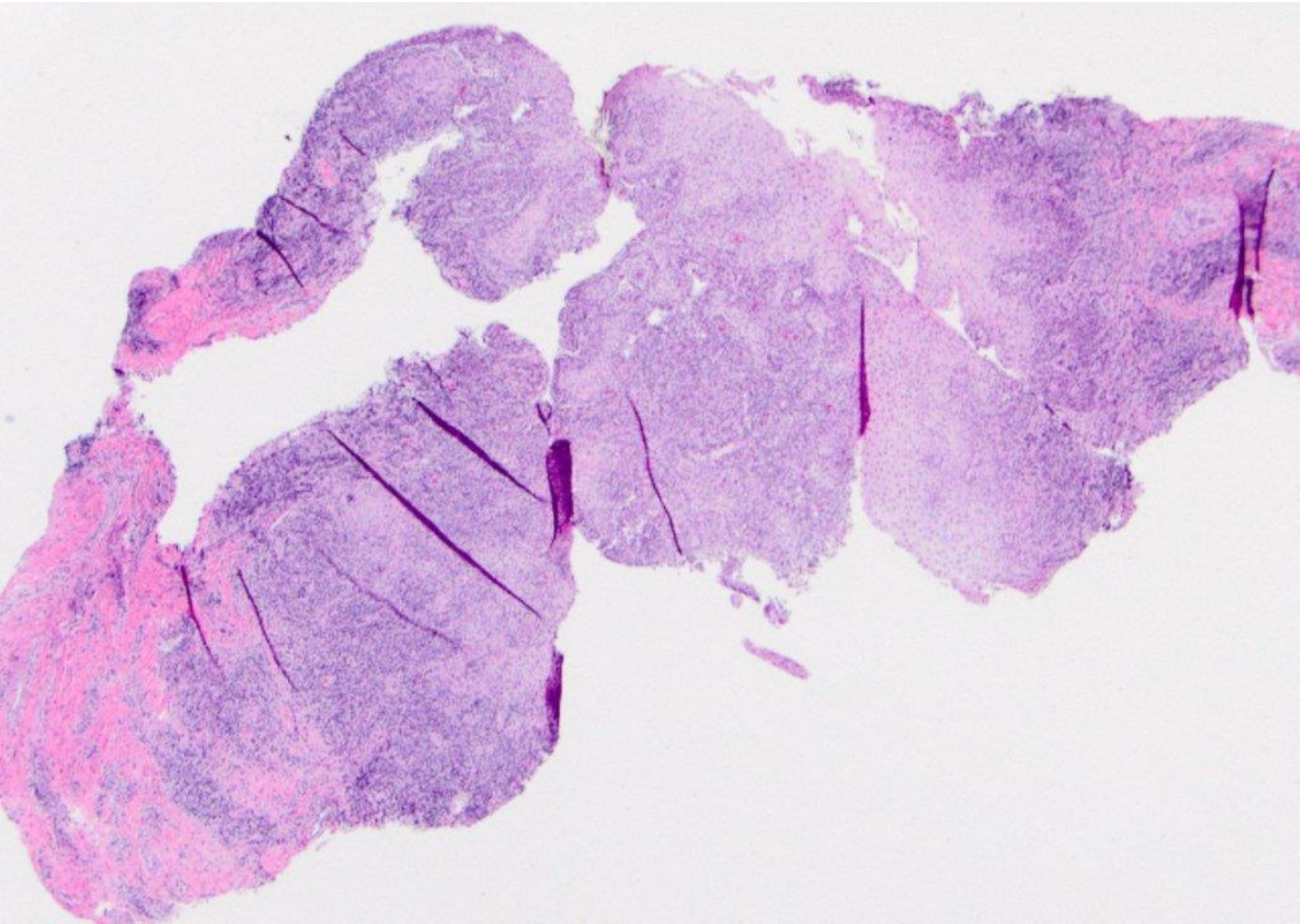




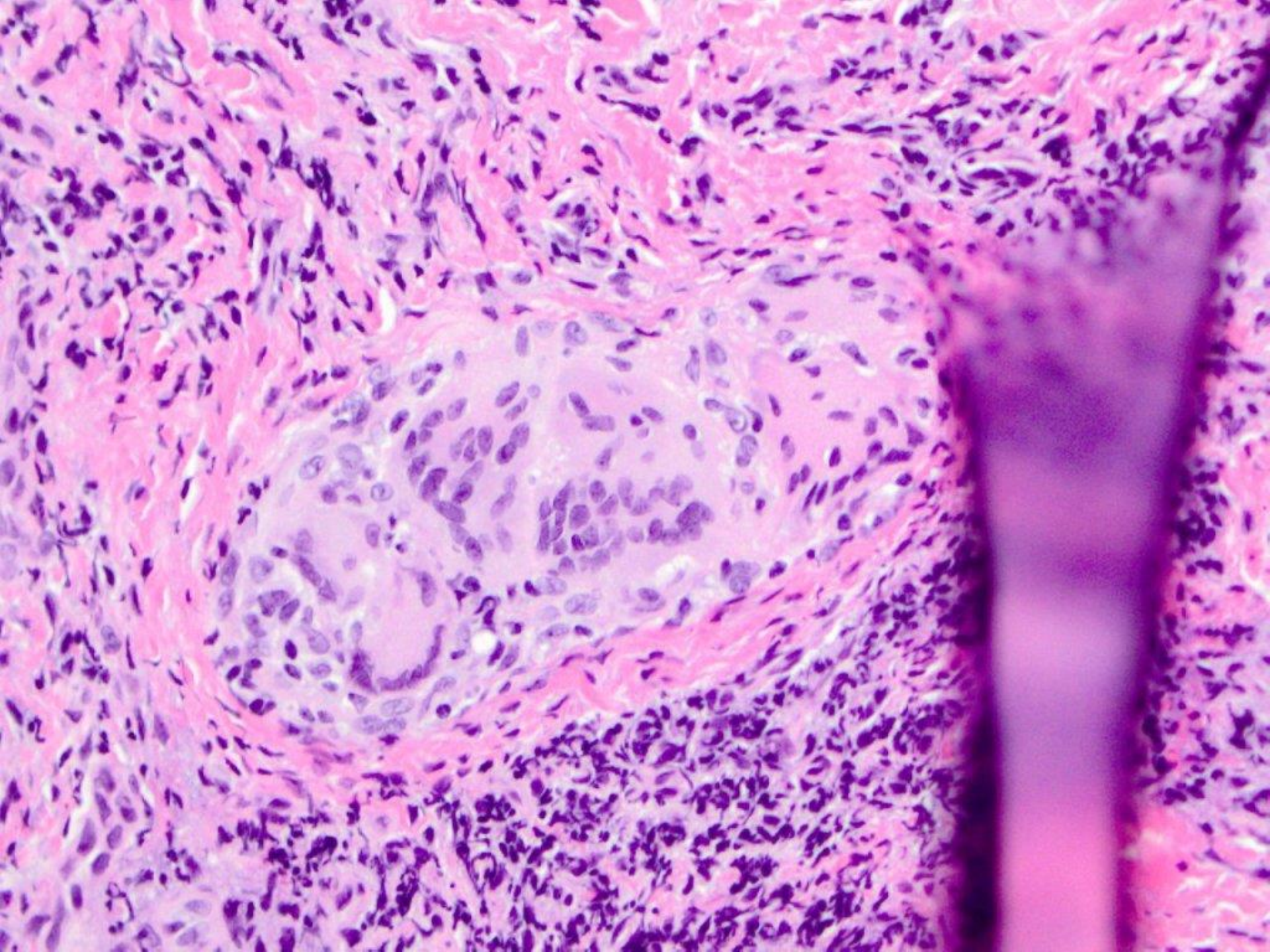
neurofibroma (with mast cells)



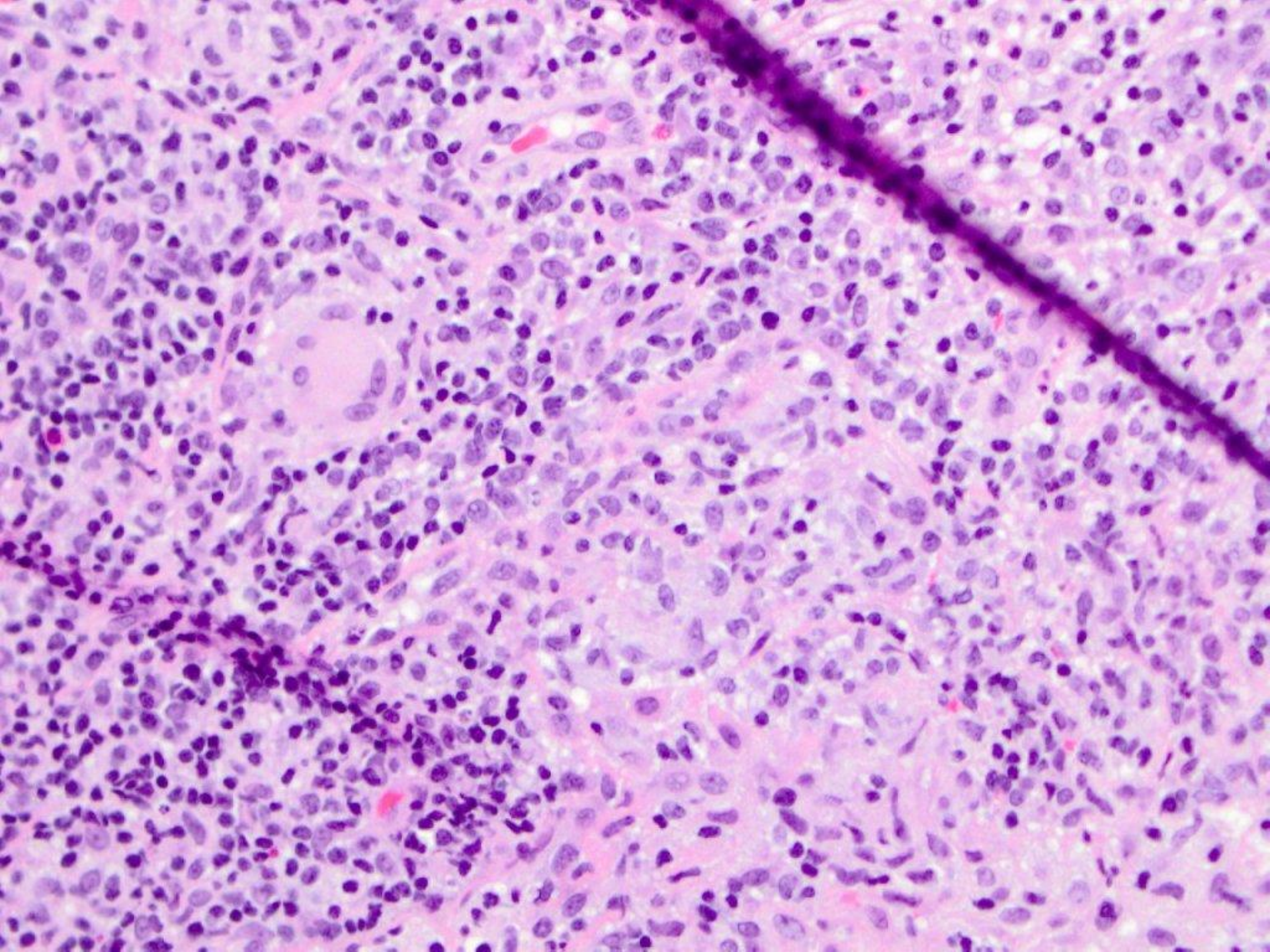
11 year old with weight loss, swollen upper lip and swollen gingiva



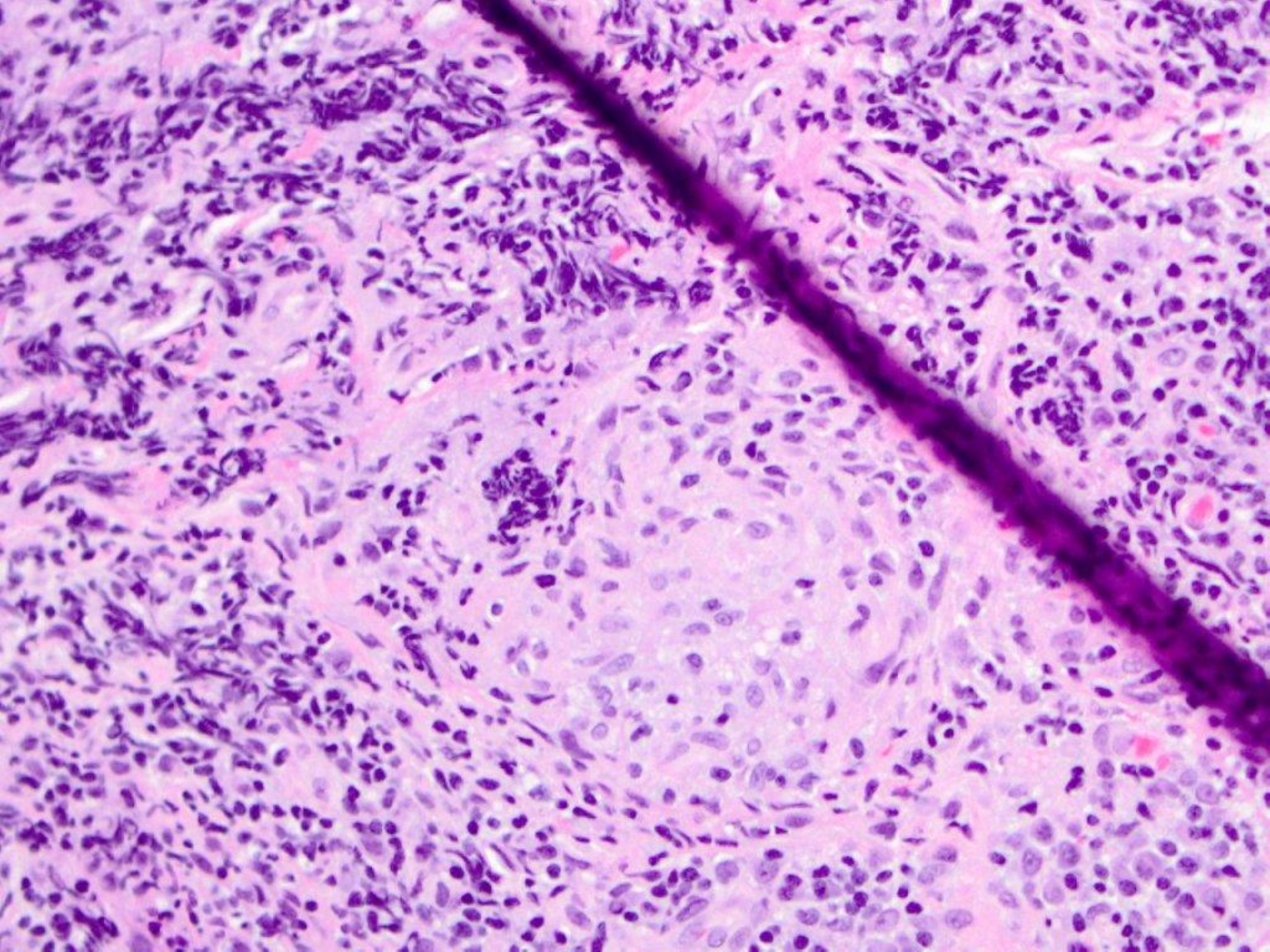




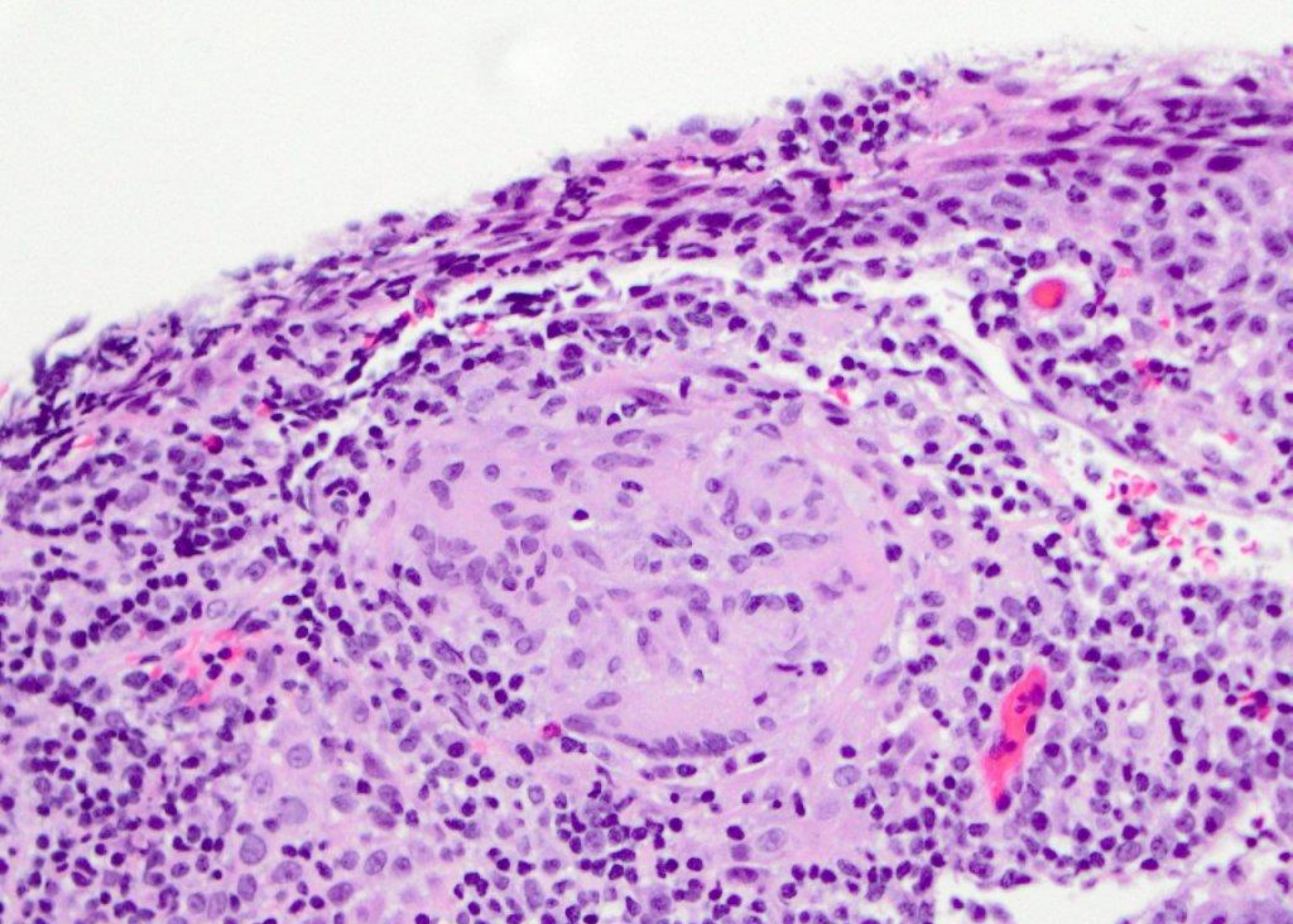








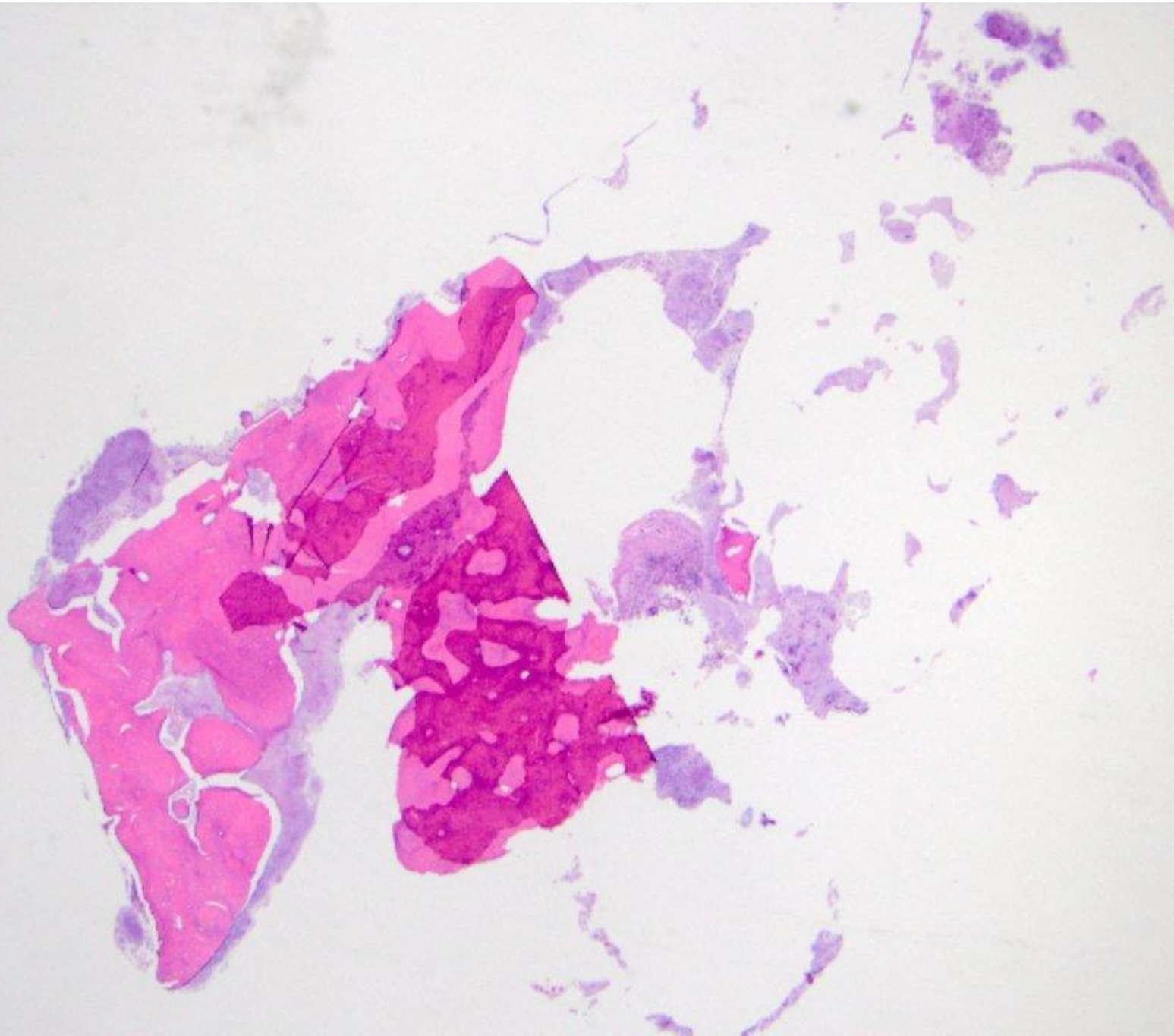




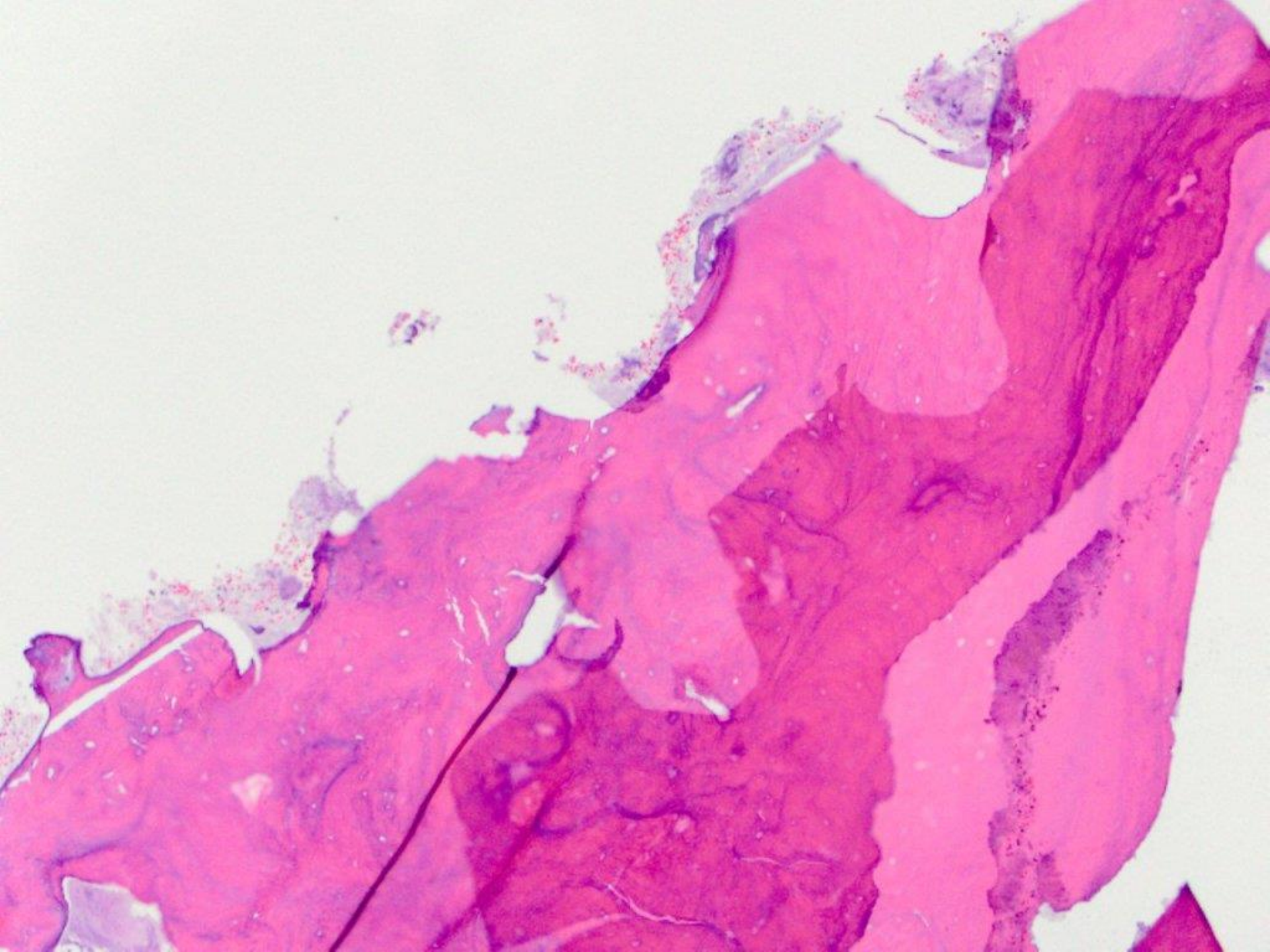
Granulomatous inflammation (c/w orofacial granulomatosis; pt being worked up for Crohn's Disease)



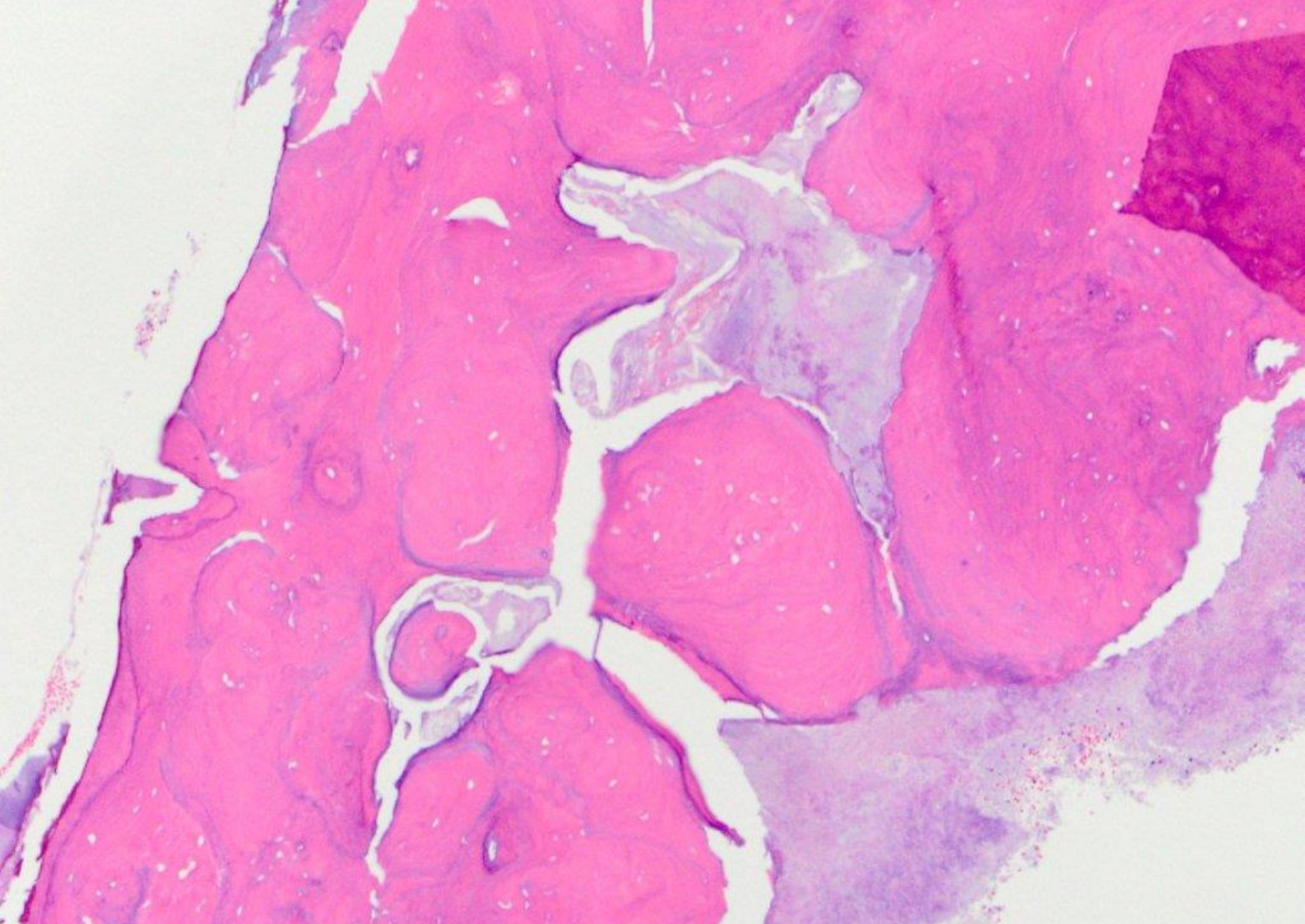
trephined implant











sequestrum and bacterial debris (consistent with a mature osteocementum/BFOL)